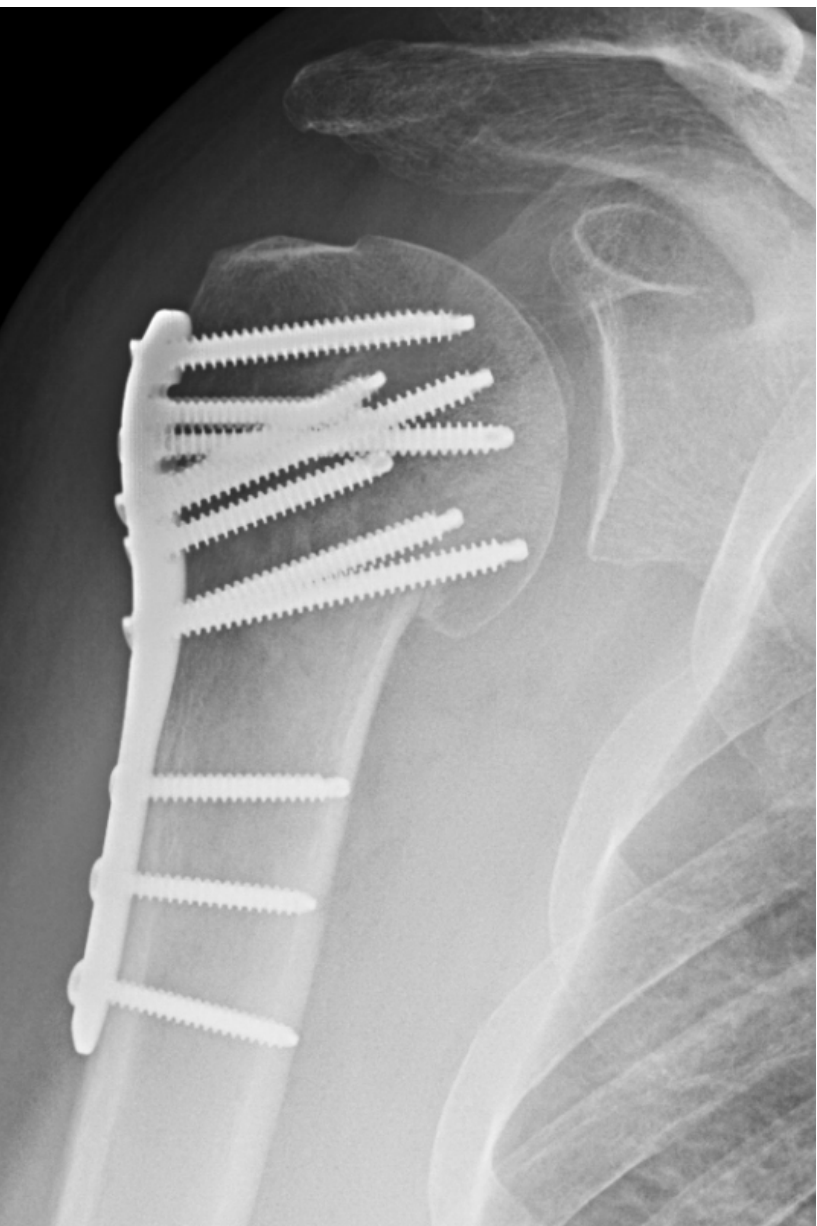

Comminuted Proximal Humerus Fracture

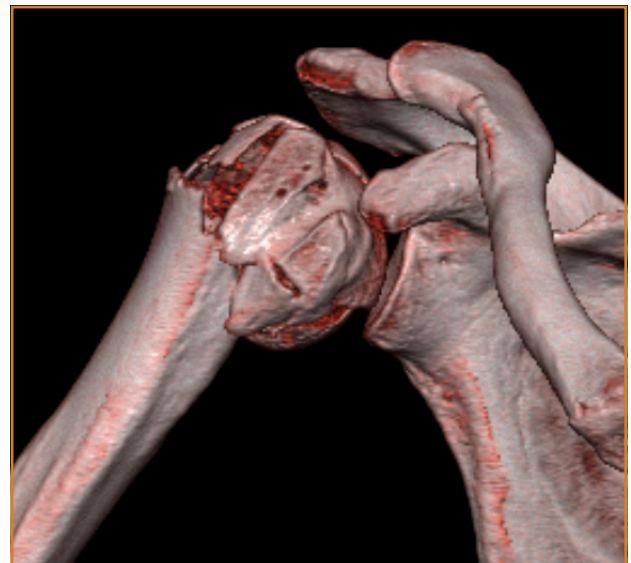
Proximal Humerus System

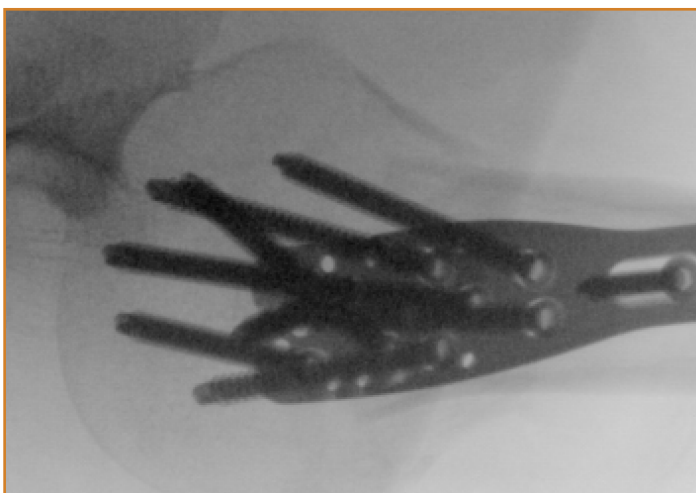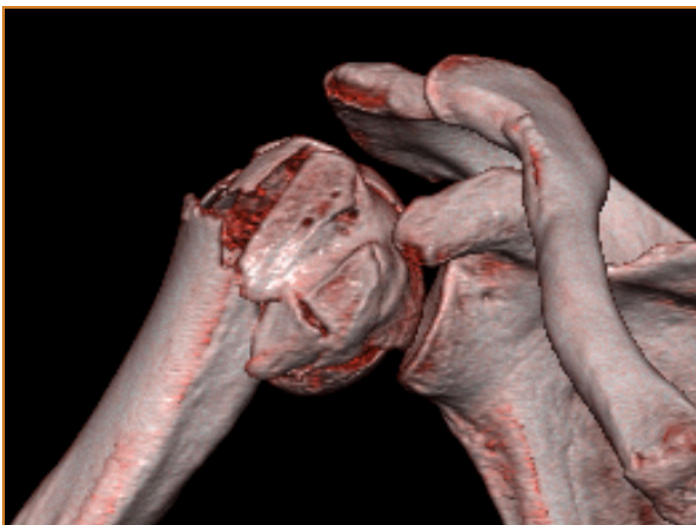Case Study | Dr. Justin Haller



Patient History

A 46 year old right hand dominant male struck a road sign while riding his motor cycle and experienced right shoulder pain. The patient was traveling 30 MPH. He was not helmeted, but denied loss of consciousness. The patient sustained no other injuries. Radiographs and CT scan of the right shoulder demonstrated a comminuted proximal humerus fracture.





Treatment

Given the patient's age and amount of deformity, he was indicated for operative fixation of his proximal humerus fracture. With the greater tuberosity fragment, it was decided to do a deltoid split approach to have easier access.

A standard deltoid split approach was used and the axillary nerve was identified and protected. The greater tuberosity and lesser tuberosity fragments were identified and secured with #2 Fiberwire suture. The head, greater tuberosity, and lesser tuberosity fragments were reduced and wired together with 0.62 Kirschner wires and then the humeral shaft was reduced to the proximal segment. The plate was positioned anatomically and was fixed to the humeral shaft using 3.5mm non-locking fasteners. Locking 4.0mm fasteners were placed in the humeral head and all wires were removed. The suture was then placed through the wire holes in the plate and tied.

Follow-Up

The patient was discharged from the hospital on post-operative day 1. The patient started active assisted shoulder range of motion at 1 week post-operatively. At 3 months follow-up, the patient had 0-130 active elevation and had returned to his job as a line cook at a local restaurant.

Clinical Advantages of UnifiMI

1. The UnifiMI 4.0mm fasteners allow for improved bone capture and engagement in the humeral head, which is notorious for having poor bone quality.
2. The UnifiMI technology resists multi-planar loads which is imperative in the shoulder as patients initiate early multidirectional motion to prevent shoulder stiffness.
3. The proximal humerus plate has the ability to place two calcar screws and allows for sufficient multidirectional fastener spread within the humeral head.
4. The metaphyseal short drill guide avoids stretching the axillary nerve while using the deltoid split approach.

These materials contain information about the products that may or may not be available in any particular country or may be available under different trademarks in different countries. The products may be approved or cleared by governmental regulatory organizations for sale or use with different indications or restrictions in different countries. Products may not be approved for use in all countries. Nothing contained on these materials should be construed as a promotion or solicitation for any product or for the use of any product in a particular way which is not authorized under the laws and regulations of the country where the reader is located.



75 West 300 N, Suite 150
Logan UT, 84321
Phone: 1-800-969-0639
info@osteocentric.com
osteocentric.com