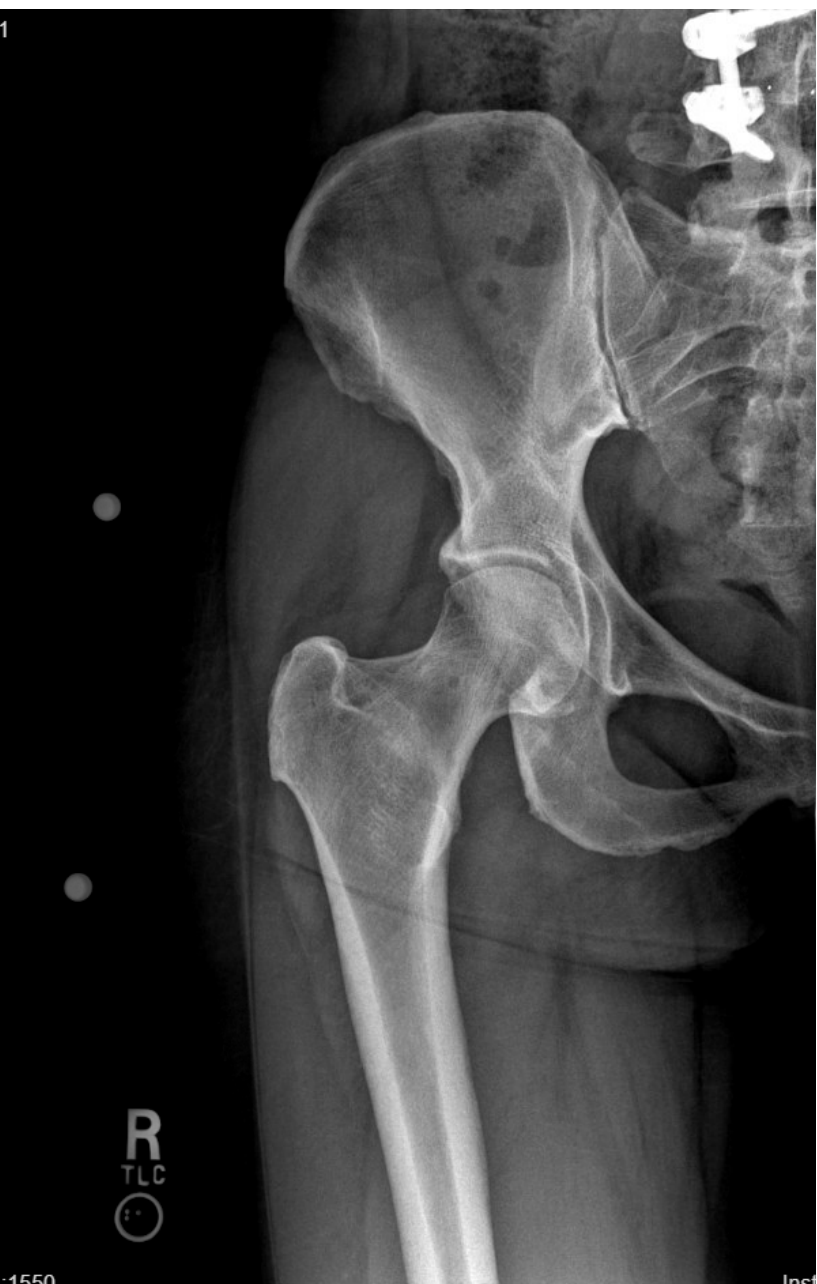

# Hip Stress Fracture

## 7.0mm & 8.0mm Cannulated Fastener System

### Case Study | Dr. Michael Weaver



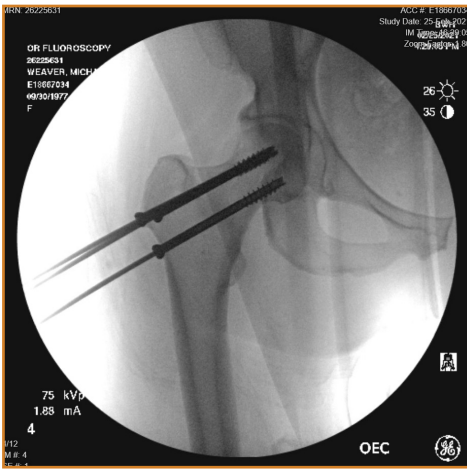
#### Patient History

A 43-year-old woman presents with progressive right hip pain. She has a history of a connective tissue disorder and a previous spinal fusion. She is active and enjoys running and cycling. Over the last 2 months she has had progressive pain in her right groin that has limited her ability to exercise and she has developed a limp. An MRI confirmed a near complete stress fracture of the femoral neck. Despite an active lifestyle she has a history of osteoporosis and has had stress fractures of the lower extremity before.

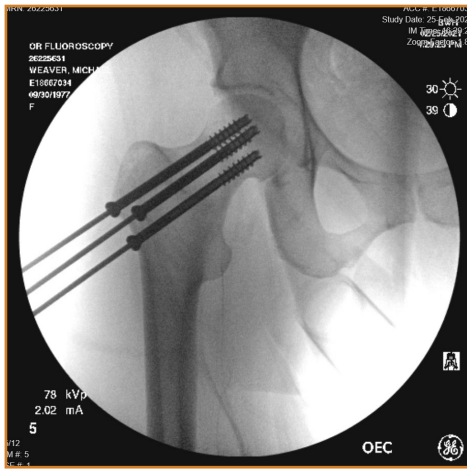
After discussion of the risks and benefits of both conservative and operative treatment the patient elected to proceed with percutaneous fixation of her femoral neck with a goal of preventing displacement of her fracture and to facilitate healing.

#### Treatment

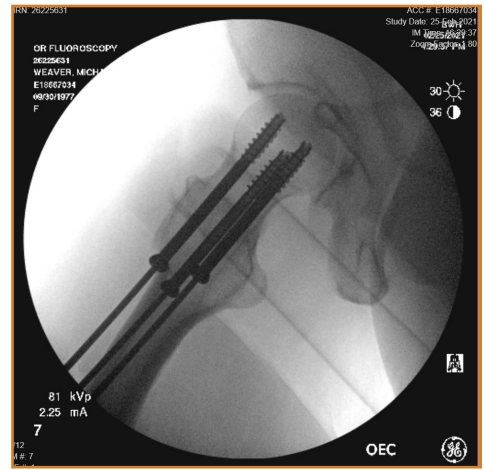Surgery was performed under general anesthesia on a fracture table to aid in positioning. A small incision was made over the right hip and under fluoroscopic guidance 3 guide wires were advanced across the lateral cortex of the femur into the femoral head and neck. Care was taken to ensure that the start point of the most inferior wire was above the level of the lesser trochanter to avoid a stress riser effect. 3 cannulated fasteners were placed resulting in excellent purchase in the femoral head.



Intra-Op



Intra-Op

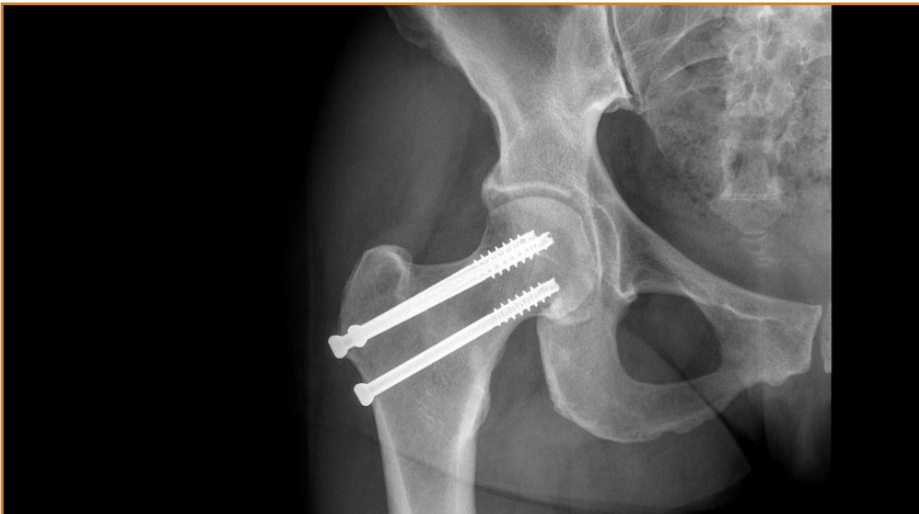


Intra-Op

## Clinical Advantages of UnifiMI

In this case the cannulated OsteoCentric fasteners were advantageous primarily for 2 reasons:

1. The UnifiMI thread technology allowed for optimal purchase within the femoral head. Having both 7.0 and 8.0 mm options provides flexibility and maximizing thread purchase. Despite her active lifestyle this patient has osteoporosis and the UniFiMI technology maximizes purchase in compromised bone.
2. The 24 mm thread-form length optimizes purchase within the femoral head and allows for maximal compression across the stress fracture.



Follow Up

## Follow-up

At 4 weeks follow-up the patient had no hip or groin pain. Her incision had healed nicely and she was walking without assistance. At 3 months she began progressive impact training and a gradual return to running.

These materials contain information about the products that may or may not be available in any particular country or may be available under different trademarks in different countries. The products may be approved or cleared by governmental regulatory organizations for sale or use with different indications or restrictions in different countries. Products may not be approved for use in all countries. Nothing contained on these materials should be construed as a promotion or solicitation for any product or for the use of any product in a particular way which is not authorized under the laws and regulations of the country where the reader is located.



75 West 300 N, Suite 150  
 Logan UT, 84321  
 Phone: 1-800-969-0639  
 info@osteocentric.com  
 osteocentric.com