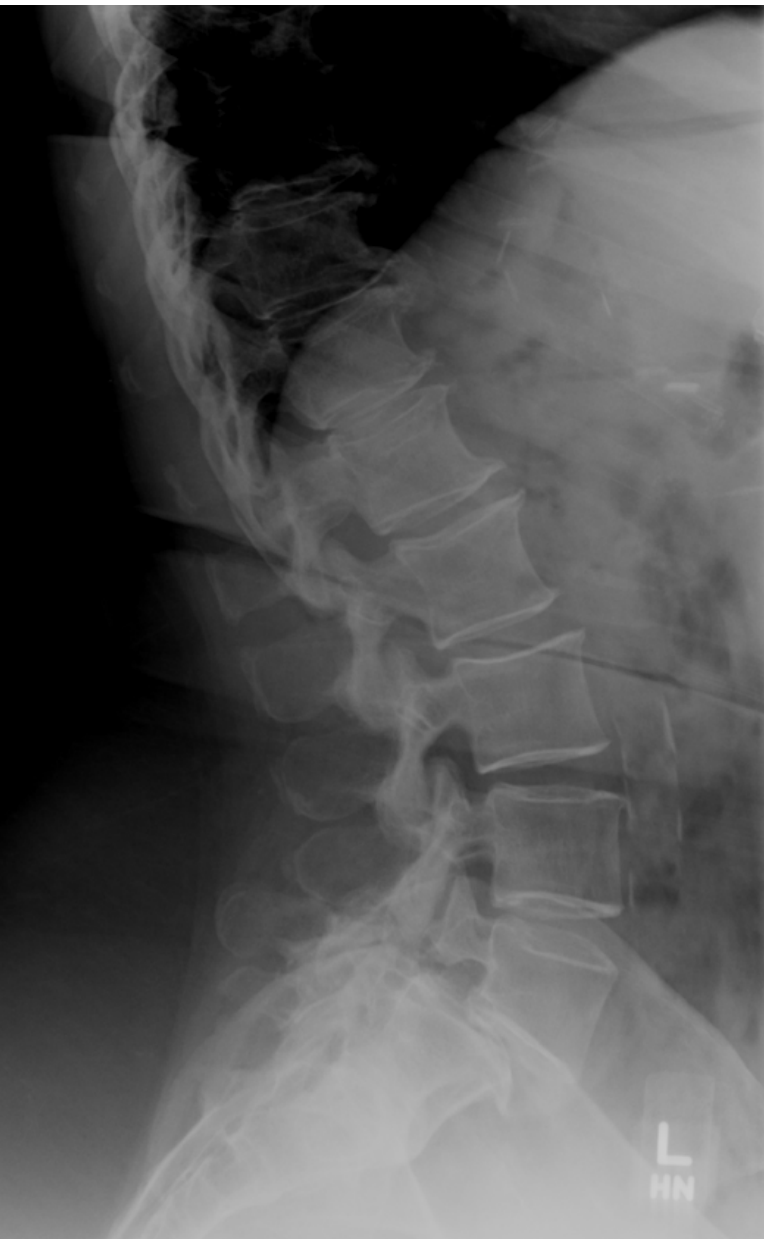

# Grade III Isthmic Spondylolisthesis

OsteoCentric Spine MIS Pedicle Fastener System

## Case Study | C. Chambliss Harrod, MD

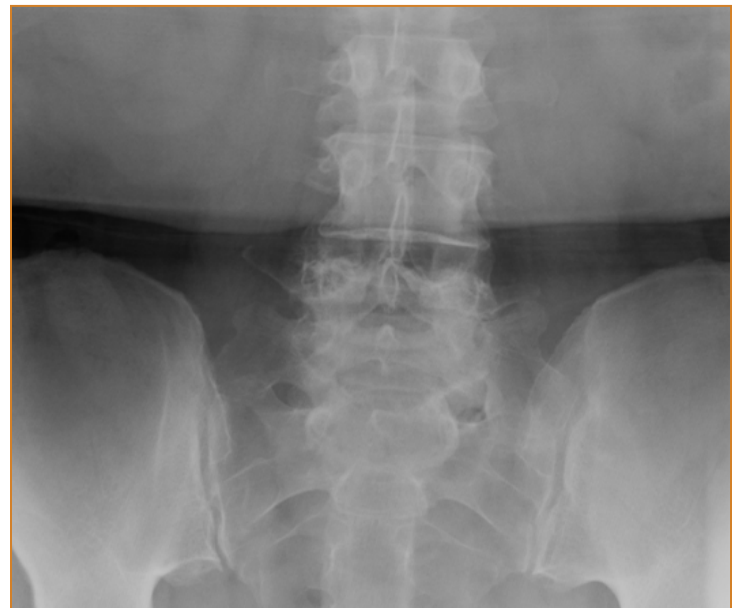

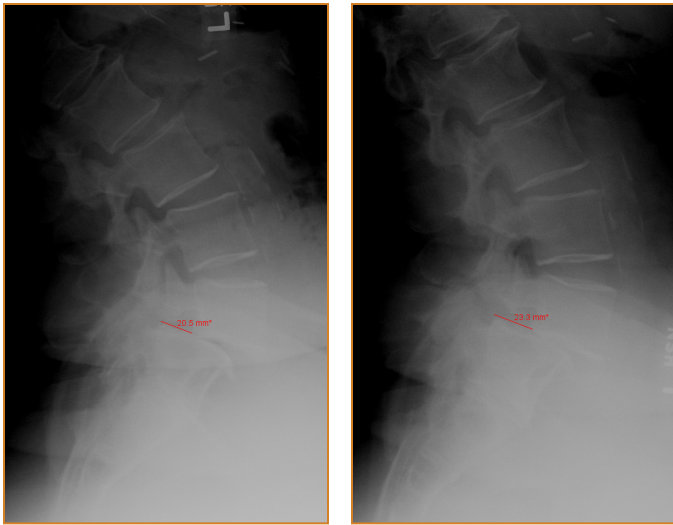
### Patient History

66 year-old female with a 10-year history of worsening low back, right buttock, and right leg pain exacerbated by recent fall. Pain worse with standing at 4+/5 BLE. Grade 2/3 bilateral L4 pars defect at the sacralized L5 segment. Transitional anatomy at lumbosacral junction. Patient experienced 80% relief after right L5/S1 TFESI that lasted 3 weeks. Transitional anatomy was visible at lumbosacral junction.

### Pre-Op Surgical Plan

L5-S1 ALIF with stand alone cage with single screw fixation at S1 to allow: Minimally Invasive L5-S1 PSF with Instrumentation/Fastener placement and reduction of Grade III Isthmic Spondylolisthesis.





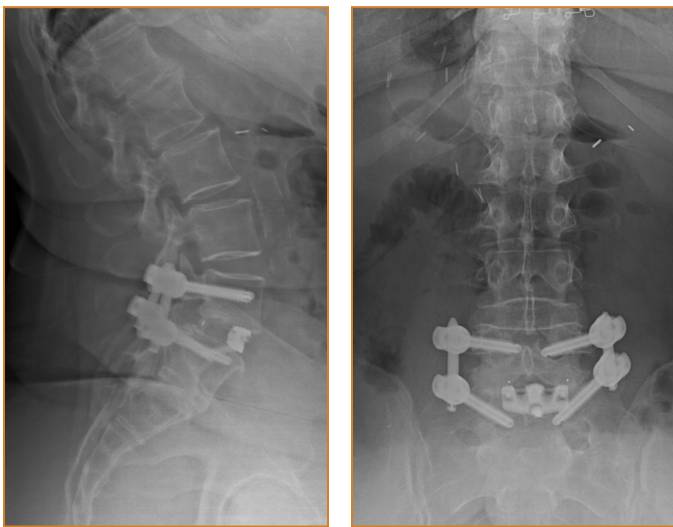
## Surgical Procedure

### L5-S1 ALIF:

- Regular table with positioning
- Pfannenstiel 5 cm incision (low transverse)
- Left side retroperitoneal approach with 2 renal vein retractors
- Bovie into the L5-S1 disk space then AP flouroscopy to confirm midline then swing to Lateral
- 5-1 anterior discectomy/release with cobb bilateral
- Trial then remove posterior disk to PLL to fully mobilize segment
- Placement of Cage based on S1 (not L5) posterior vertebral line
- Single screw fixation into S1 so cage can't migrate anteriorly
- Final Flouroscopic Shots – Lateral then AP

### POSTERIOR:

- Open Jackson table
- Bilateral Wiltze incisions
- Exposure then decortication of L5 TP and Sacral ala and graft placement prior to instrumentation
- Jamshidi access standard MIS technique to base of vertebral body then Split wire Guidewire
- Tap line to Line then placement Bilateral L5 then S1 fasteners
- Stim screws with Neuromonitoring then, final tighten down Bilateral S1 set caps then, use bilateral equal sequential reduction of slip via L5 fastener tightening
- Final Flouroscopic Shots Lateral then AP



## Post-Op

Evaluation at 2-week post-op, patient had normal leg strength with complete resolution of right leg pain. At 3 months, patient evaluation showed a VAS back 1/10, VAS Leg 0/10, and XR looked perfect.

## Clinical Advantages of UnifiMI®

UnifiMI thread technology allows for optional purchase in postmenopausal Caucasian female with osteoporotic bone in high risk case for inadequate reduction, residual foraminal stenosis and radiculopathy. Excellent immediate fixation allowed complete reduction of significant instability with confidence that no loss of fixation would occur.

These materials contain information about the products that may or may not be available in any particular country or may be available under different trademarks in different countries. The products may be approved or cleared by governmental regulatory organizations for sale or use with different indications or restrictions in different countries. Products may not be approved for use in all countries. Nothing contained on these materials should be construed as a promotion or solicitation for any product or for the use of any product in a particular way which is not authorized under the laws and regulations of the country where the reader is located.



75 West 300 N, Suite 150  
Logan UT, 84321  
Phone: 1-800-969-0639  
info@osteocentric.com  
osteocentric.com