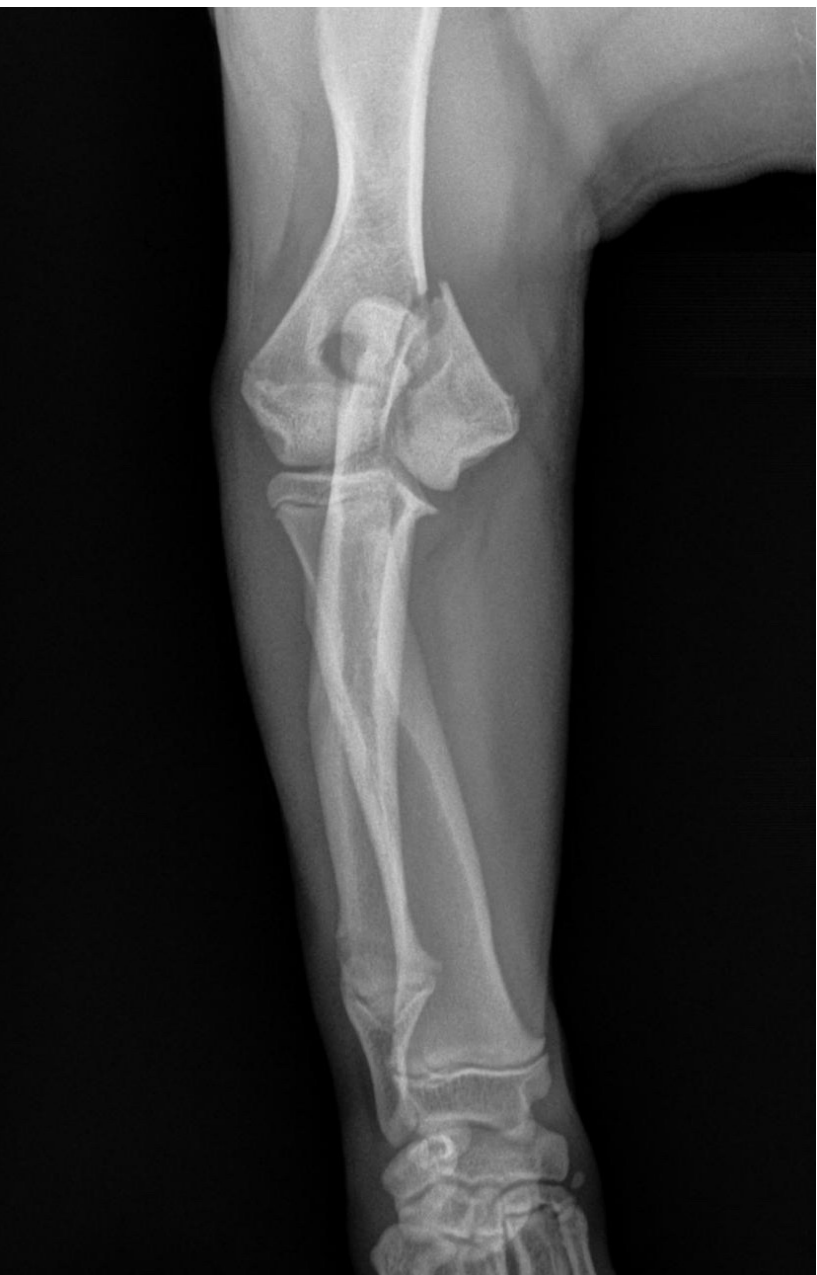

# Salter-Harris Grade IV Distal Humerus Fracture

UnifiMI® Headless Compression System

## Case Study | Dr. Daniel Mertens

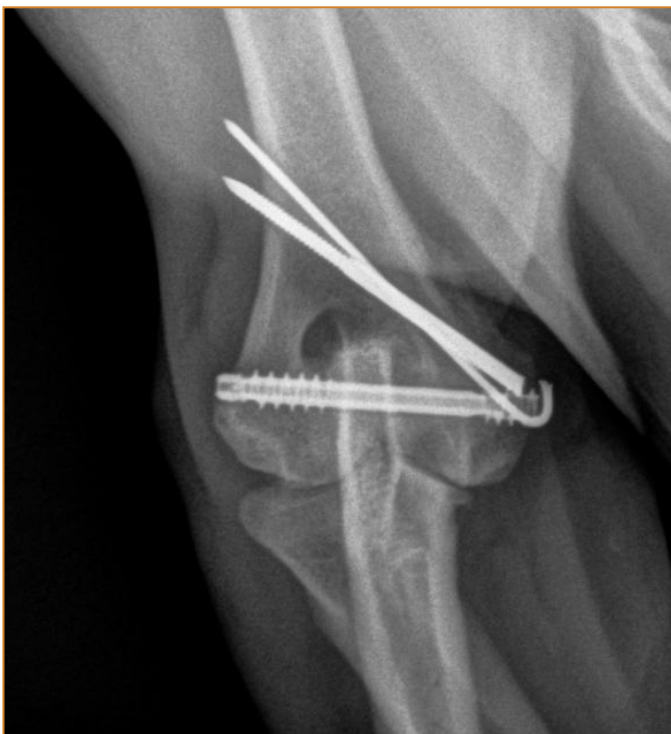


### Patient History

The patient was a 22 week old male intact French Bulldog who presented to our emergency service with a non-weight bearing lameness of the right thoracic limb after jumping off the bed earlier in the day. Radiographs demonstrated a Salter-Harris grade IV fracture involving the medial portion of the humeral condyle.

### Pre-Op Surgical Plan

The patient was transferred to our surgical service for internal fixation and stabilization. We planned to use an Osteocentric Headless Compression Fastener with UnifiMI thread geometry to create compression across the two halves of the condyle. We also planned to place k-wires across the medial epicondylar ridge fracture for anti-rotational purposes.

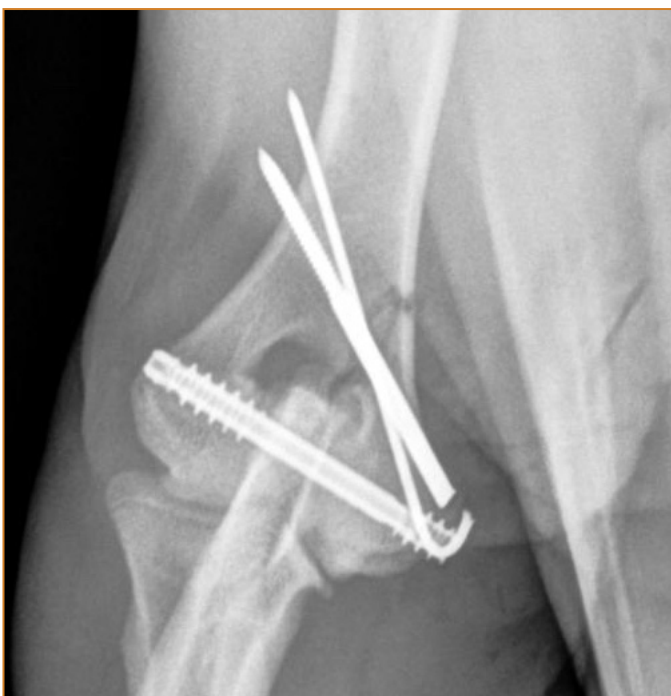

## Surgical Procedure

A routine medial approach to the right distal humerus and epicondylar region was performed. The fracture was reduced using the epicondylar fracture line to judge anatomic reduction. A 1.6mm k-wire was placed across the epicondylar fracture line to maintain reduction and to resist rotation in advance of the headless compression fastener being inserted. A 3.8mm Osteocentric Headless Compression Fastener was then placed in routine fashion, first using a transcondylar k-wire to confirm proper positioning and then overdrilling using a cannulated drill bit. Subjectively, a large amount of compression was felt to be achieved. A 2.0mm Ellis pin was then placed across the epicondylar fracture to augment fixation. Closure was routine.

## Follow Up

Complete healing was noted on radiographs taken seven weeks following surgery. No shifting of the fracture segments or implants was noted compared to post-operative radiographs indicating a high degree of stability.



## Clinical Advantages of UnifiMI®

Headless compression fasteners with UnifiMI geometry provided us with numerous advantages over a traditional repair with a lag screw or positional screws. Lag screws require overdrilling and lack of a tight fit between the screw and the glide hole allow for micromotion that can be predisposed to failure. Positional screws do not suffer from this disadvantage but the only compression that is achieved is that which is present at the time of screw placement (either through manual compression or reduction forceps). Both techniques require use of a washer in the soft bone of such a young patient and screw loosening is not an uncommon complication. By using a UnifiMI headless fastener, a high level of compression can be achieved with a nearly non-existent risk of the implant backing out. Because compression is created by a differential pitch, overdrilling for lag screw placement is not necessary and a tight fit between implant and bone is maintained due to the UnifiMI thread interface.

These materials contain information about the products that may or may not be available in any particular country or may be available under different trademarks in different countries. The products may be approved or cleared by governmental regulatory organizations for sale or use with different indications or restrictions in different countries. Products may not be approved for use in all countries. Nothing contained on these materials should be construed as a promotion or solicitation for any product or for the use of any product in a particular way which is not authorized under the laws and regulations of the country where the reader is located.



75 West 300 N, Suite 150  
Logan UT, 84321  
Phone: 1-800-969-0639  
info@osteocentric.com  
osteocentric.com