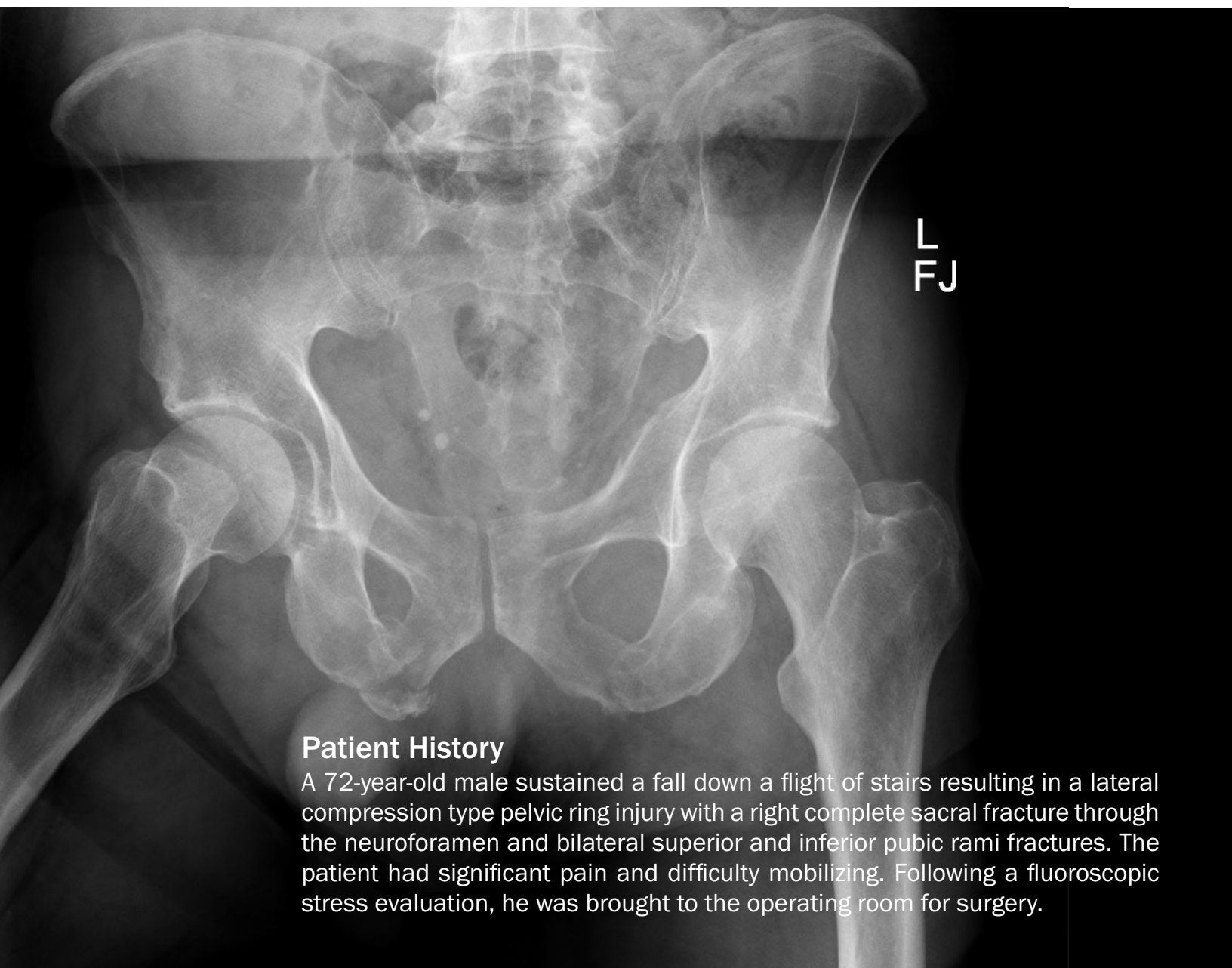

Pelvic Ring Fracture

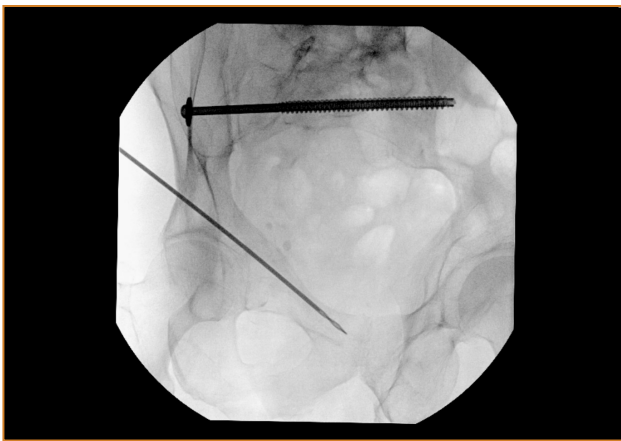
7.0mm & 8.0mm Cannulated Fastener System

Case Study | Dr. Michael Weaver

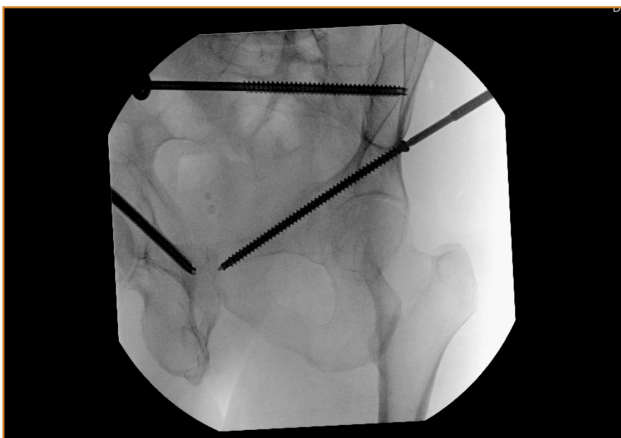


Patient History

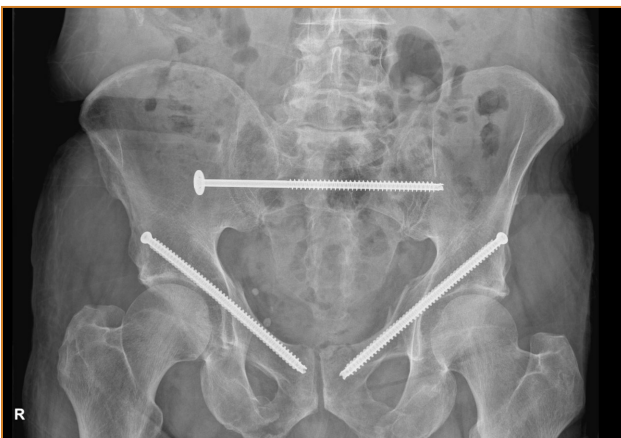A 72-year-old male sustained a fall down a flight of stairs resulting in a lateral compression type pelvic ring injury with a right complete sacral fracture through the neuroforamen and bilateral superior and inferior pubic rami fractures. The patient had significant pain and difficulty mobilizing. Following a fluoroscopic stress evaluation, he was brought to the operating room for surgery.



Intra-Op



Intra-Op



Follow Up

Treatment

Under fluoroscopy it was determined the patient had significant displacement of the rami fractures bilaterally with lateral compression of the pelvis. Given this the decision was made to proceed with percutaneous fixation of the pelvic ring with a goal of providing stability, improving his pain control, and improving his ability to ambulate. First the sacroiliac fastener was placed. A guide wire was carefully advanced across the sacroiliac joint into the body of S2. The patient had sacral dysmorphism making the S2 bony corridor safer. Once the sacroiliac fastener was in place attention was turned towards the anterior pelvic ring. Guide wires were advanced from the lateral table of the pelvis, just above the hip joint, across the acetabulum and into the superior pubic ramus. Fully threaded fasteners were placed to provide stability of the anterior ring.

Clinical Advantages of UnifiMI®

In this case the cannulated OsteoCentric fasteners were advantageous for multiple reasons:

1. The variable length thread form optimizes purchase within the sacrum and pelvis. Traditional cannulated screws offer limited thread length options to obtain purchase in the sacrum. Here over 60 mm of threads are engaged in the pelvis maximizing compression across the sacral fracture.
2. An over-sized washer option is ideal for compromised bone preventing penetration of the fastener head or washer through the lateral table of the pelvis.
3. The UniFiMI thread technology allows for optimal purchase within compromised bone.
4. The OsteoCentric fastener length options allow for maximal flexibility in placing fasteners through the safe bony corridors of the pelvis and sacrum.

Follow-up

The patient had immediate reduction of pain postoperatively. Post-op day 1 the patient was able to stand and ambulate with assistance. He was discharged to rehab facility and by 4 weeks was walking without assistance.

These materials contain information about the products that may or may not be available in any particular country or may be available under different trademarks in different countries. The products may be approved or cleared by governmental regulatory organizations for sale or use with different indications or restrictions in different countries. Products may not be approved for use in all countries. Nothing contained on these materials should be construed as a promotion or solicitation for any product or for the use of any product in a particular way which is not authorized under the laws and regulations of the country where the reader is located.



75 West 300 N, Suite 150
Logan UT, 84321
Phone: 1-800-969-0639
info@osteocentric.com
osteocentric.com