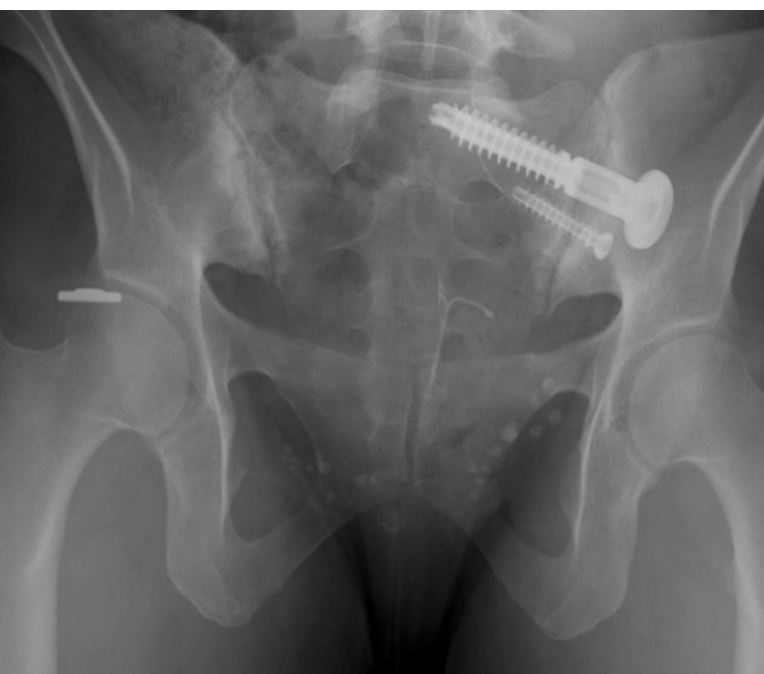


MIS Primary SI Joint Fusion - 36 y.o. Active Female

OsteoCentric Integrity-SI® Fusion System

Case Study | Marko Tomov, MD



Patient History

Patient is a 36-year-old active female with several year history of low back pain that also radiates down her bilateral lower extremities in the posterior thighs to her knees. She has gone through several non-operative modalities, including formal physical therapy, chiropractic care, massage therapy, variety of pain medications, and bilateral SIJ injections with near 100% relief of symptoms, albeit temporary. *Fig.1*

Pre-Op Surgical Plan

After exhausting all non-operative measures, given that the patient's pain could be reproduced bilaterally in all 5 sacroiliac joint physical exam maneuvers, along with her near 100% relief of symptoms with CT-guided injections of her bilateral SI joints, she was deemed a great candidate for MIS primary SI joint fusion. Given that her left side was the more symptomatic side, she opted to start with a left SI joint fusion. *Fig. 2*

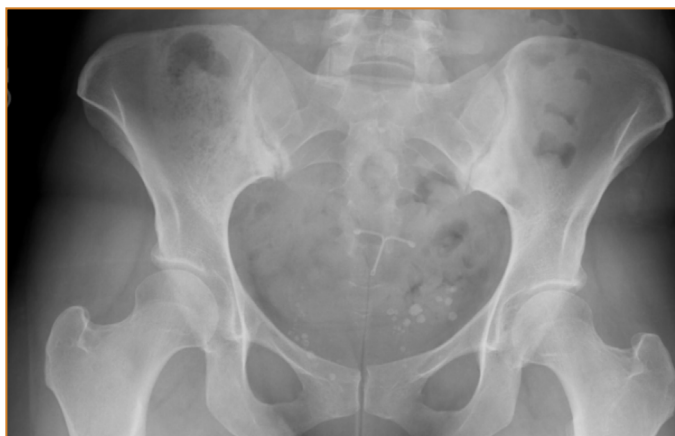

Figure 1

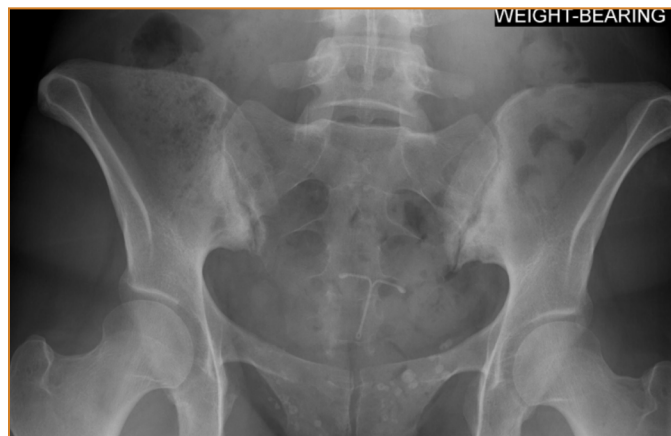

Figure 2

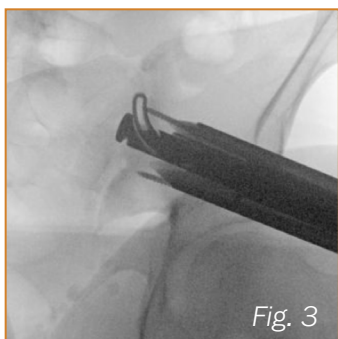


Fig. 3

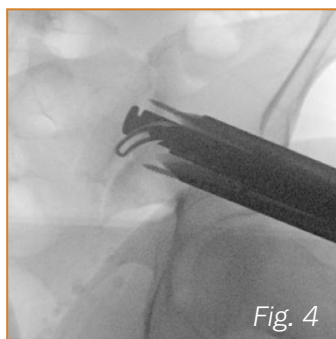


Fig. 4

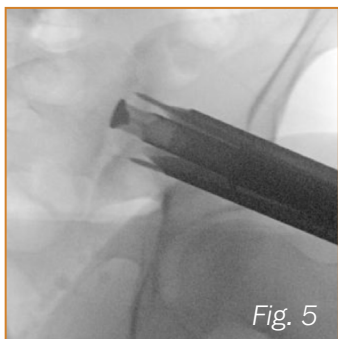


Fig. 5

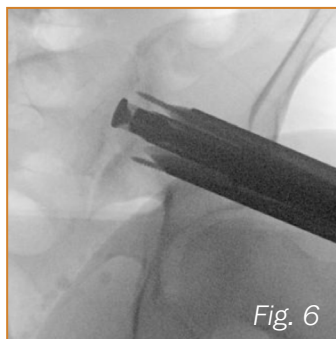


Fig. 6

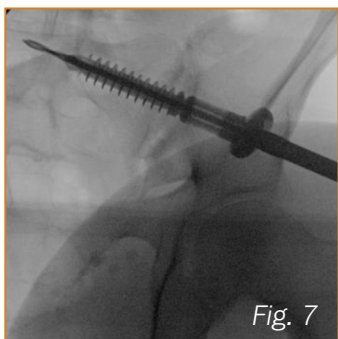


Fig. 7

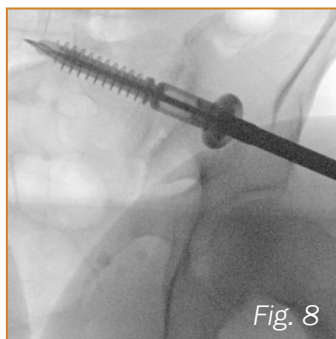


Fig. 8

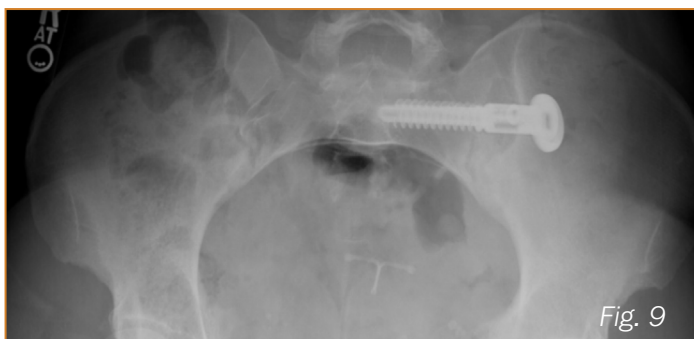


Fig. 9

Surgical Procedure

The patient was positioned prone on a flat-top style table and fluoroscopy was brought in to assure the appropriate inlet and outlet views could be obtained prior to starting the procedure. Appropriate pin placement was achieved using the inlet and outlet fluoroscopy views. The drilling step was performed over this optimally placed pin to not only create the track for the implant but to collect adequate autograft. The zone of fusion across the SI joint was aggressively decorticated to allow for bone to bone apposition. (Fig 3, 4) This void was back-filled with autograft and allograft to promote bony fusion (Fig 5, 6). The final implant was then inserted and maximal compression across the SI joint was achieved (Fig. 7, 8). An anti-rotation fastener was placed caudal to the main implant for added stability (Fig. 9 - *Anti-rotation fastener hidden in inlet view*).

Post-Op

This patient had 100% resolution of her pre-operative left SI joint pain as early as the 6 week post-operative mark, and continued to do well with no complications at the 3 month post-operative visit. Given that her right SI joint continued to aggravate her, she opted to move forward with scheduling a right MIS SI joint fusion using the OsteoCentric system in the future.

Clinical Advantages of Integrity-SI:

The expandable blade via Blade-X technology allows for a zone of decortication across the SI joint to achieve bone to bone apposition. The graft window of the primary implant along with the grafting step to fill the void allows for significant delivery of graft to further support the goal of fusion. Finally, UnifiMI and the large proximal washer facilitates significant construct stability and compression across the fusing SI joint.

These materials contain information about the products that may or may not be available in any particular country or may be available under different trademarks in different countries. The products may be approved or cleared by governmental regulatory organizations for sale or use with different indications or restrictions in different countries. Products may not be approved for use in all countries. Nothing contained on these materials should be construed as a promotion or solicitation for any product or for the use of any product in a particular way which is not authorized under the laws and regulations of the country where the reader is located.



75 West 300 N, Suite 150
Logan UT, 84321
Phone: 1-800-969-0639
info@osteocentric.com
osteocentric.com