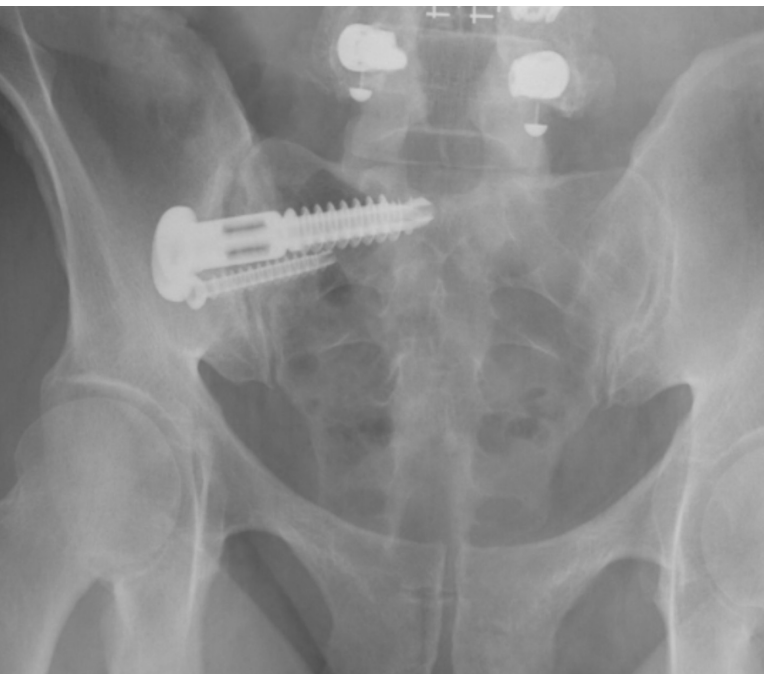


MIS Primary SI Joint Fusion - 47 y.o. Active Female

OsteoCentric Integrity-SI® Fusion System

Case Study | Marko Tomov, MD



Patient History

Patient is a 47-year-old active female with a history of L4-5 lumbar fusion presenting with persistent pain in the region of her right sacroiliac joint. This pain was exacerbated after being involved in a car accident in 2018. She failed all non-operative modalities and sought a surgical solution. *Fig.1 & 2*

Pre-Op Surgical Plan

The patient's pain on the right could be reproduced by all 5 sacroiliac joint physical exam maneuvers and she had substantial, albeit temporary, relief of her pain following an image-guided intra-articular right SI joint injection. She failed all non-operative modalities including at least 6 weeks of physical therapy, multiple medications, use of an SI joint belt, and at least two SI joint injections. At this point, the patient was indicated for a MIS primary SI joint fusion.

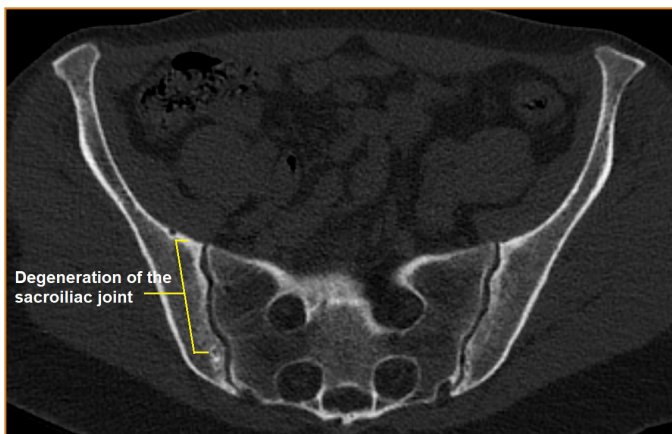


Figure 1

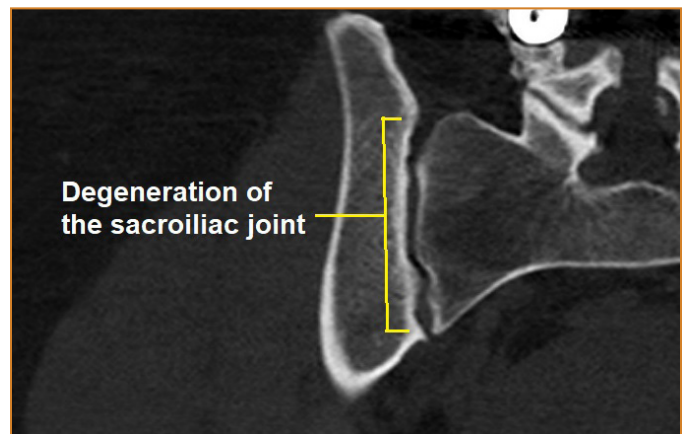
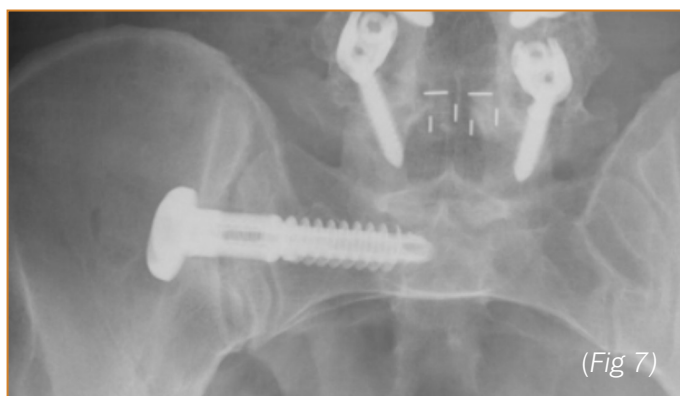
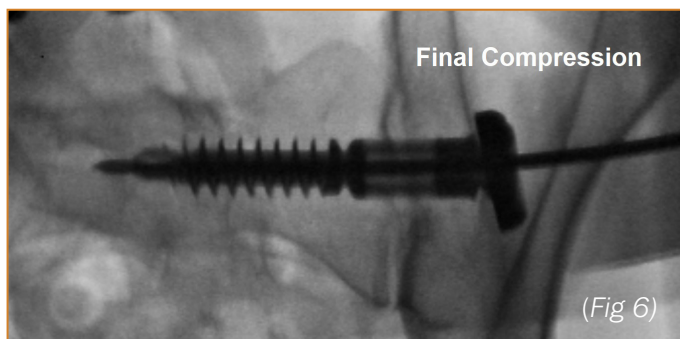
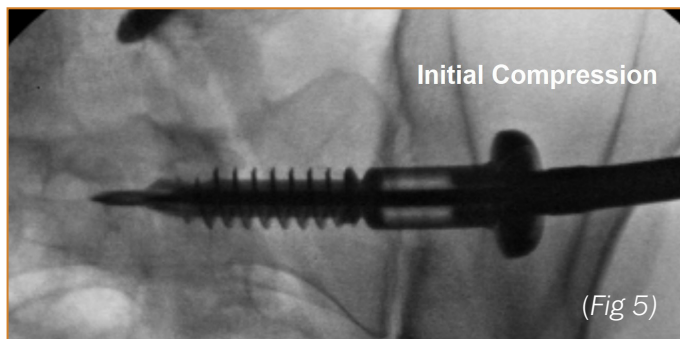
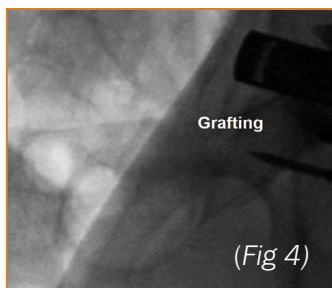
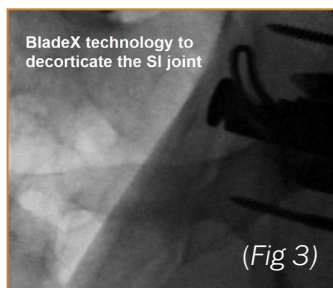


Figure 2



Surgical Procedure

The patient was positioned prone and fluoroscopy was brought in to assure the appropriate inlet and outlet views could be obtained prior to starting the procedure. These two views were used during the procedure to be certain that the starting pin, and ultimately final implant, were placed in a safe position. The drilling step allowed for the collection of ample autograft. The zone of fusion was aggressively decorticated to eventually allow for bone to bone apposition. This void was back-filled with autograft and allograft to promote bony fusion. The final implant was then inserted and maximal compression across the SI joint was achieved. An anti-rotation screw was placed caudal to the main implant for added stability. (Fig 3, 4, 5 & 6).

Post-Op

This patient had 100% resolution of pre-operative right SI joint pain by the 3-month post-operative mark. Surgical pain was resolved by the 6-week post-operative visit. At 3 months, she was back to the active lifestyle she was previously unable to be a part of secondary to her pain. (Fig. 7)

Clinical Advantages of Integrity-SI:

The Blade-X technology is unique in that it allows the surgeon to follow one of the basic orthopaedic principles of fusion: adequate joint decortication with the goal of achieving bleeding bone to bleeding bone contact. The large graft window in the primary implant can be filled with a substantial amount of autograft and allograft to further promote a fusion in the zone of the SI joint. Finally, the thread geometry and robust washer design on the main implant allows for maximal compression across the SI joint to fulfill another crucial orthopedic principle of joint fusion.

These materials contain information about the products that may or may not be available in any particular country or may be available under different trademarks in different countries. The products may be approved or cleared by governmental regulatory organizations for sale or use with different indications or restrictions in different countries. Products may not be approved for use in all countries. Nothing contained on these materials should be construed as a promotion or solicitation for any product or for the use of any product in a particular way which is not authorized under the laws and regulations of the country where the reader is located.



75 West 300 N, Suite 150
Logan UT, 84321
Phone: 1-800-969-0639
info@osteocentric.com
osteocentric.com