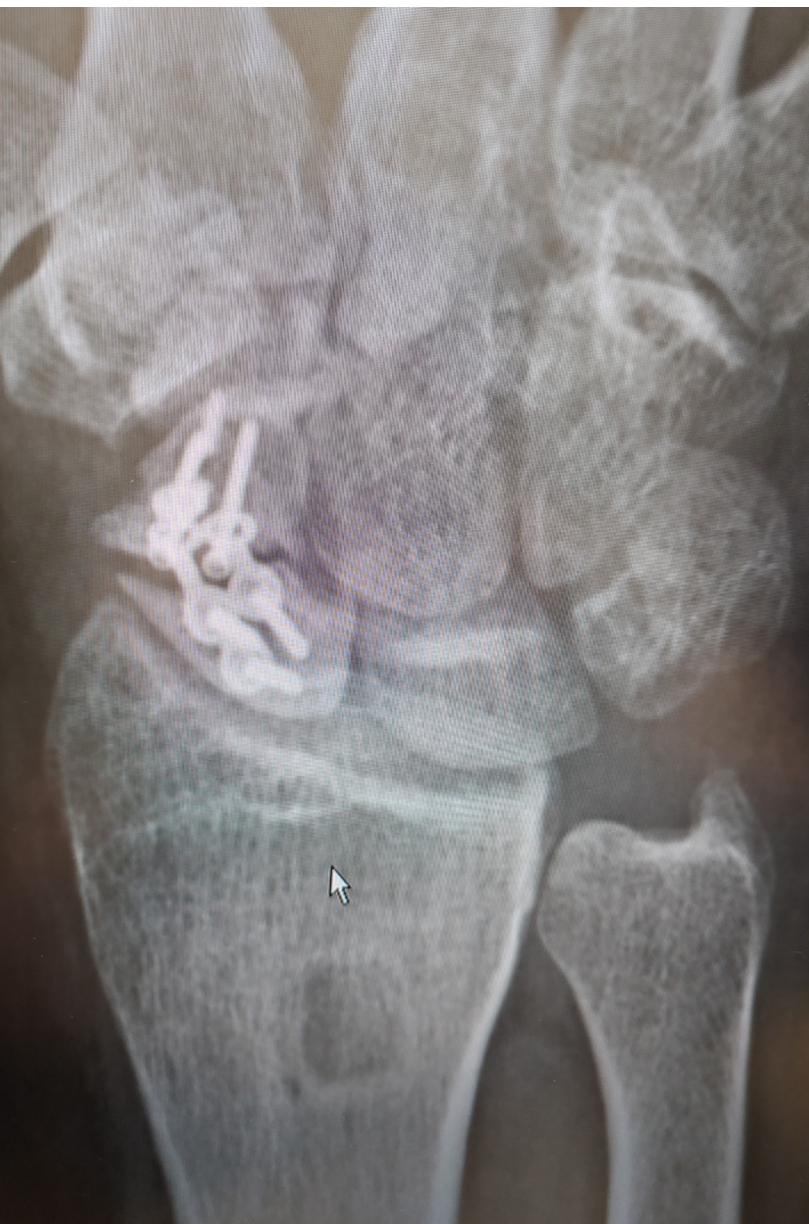

4-Corner Fusion

SNAC Wrist UnifiMI® Headless Compression System

Case Study | Dr. William Geissler



Patient History

The patient is a 47 year old male farmer with a 10 year history of right wrist pain. He presented from an outside institution with a sclerotic nonunion of the scaphoid. Previously, he had underwent a vascularized bone graft and plate fixation fracture. Despite the fixation, the scaphoid did not heal and eventually the plate broke. Pain subsequently increased with any type of motion to the wrist especially while lifting.

Treatment

On physical exam he had very limited range of motion. He had 20° extension, 10° flexion, no radial deviation and 10° ulnar deviation. Radiographs demonstrated sclerotic scaphoid nonunion with a broken plate and loose screws.

At that point, it was recommended to excise the sclerotic nonunion of the scaphoid and perform a 4-corner fusion.

Figure 1: Posterior anterior radiograph demonstrating a persistent scaphoid nonunion despite vascularized graft and plating. The source of the vascularized graft can be seen by the lucent area on the distal radius.

Surgical Procedure

The standard dorsal approach is made to the wrist. In this case an approximately 8cm skin incision was made in the midline of the dorsum of the wrist. Sharp dissection was carried down to the fascia, and thick skin flaps were elevated. The extensor pollicis longus was released from the 3rd compartment. The 2nd and 4th dorsal compartments were then opened, and a radial-based flap was made. It is important to release the 5th compartment as well so that the extensor digitorum tendon is not injured when the ulnar portion of the dorsal flap is made.

This exposed the scaphoid nonunion. The wrist was hyper-flexed and the scaphoid nonunion fracture fragment were excised (Fig.2).

Next, a joystick was placed in the lunate to control rotation. The articular cartilage of the distal aspect of the lunate and triquetrum was removed, along with the proximal aspect of the articular cartilage to the capitate and hamate (Fig.3).

Allograft bone graft was placed at the fusion site and the lunate was reduced on the capitate (Fig.4).

It is vital to correct the rotation of the lunate so it is not fused in a DISI position, decreasing wrist extension. It is also important not to overcorrect the lunate on the radial aspect of the capitate. It should line up on the mid-axis of the capitate with neutral rotation.

Guide wires are then placed. It is easy to place the guide wire too dorsally on the lunate, close attention is made to place the guide wire neutral in the anterior posterior plane of the lunate. One guide wire is placed from the lunate into the capitate, one from the lunate into the hamate, and a third guide wire is placed from the triquetrum up into the hamate. The proposed fastener lengths are then measured over the guide-wires. It is recommended that a fastener 4mm shorter is utilized than what is measured. In this manner, it allows for the implant to be inserted well up into the carpus to help decrease the chance of it injuring the articular cartilage of the distal radius. The carpal bones are drilled to the fastener length as measured (Fig 5).

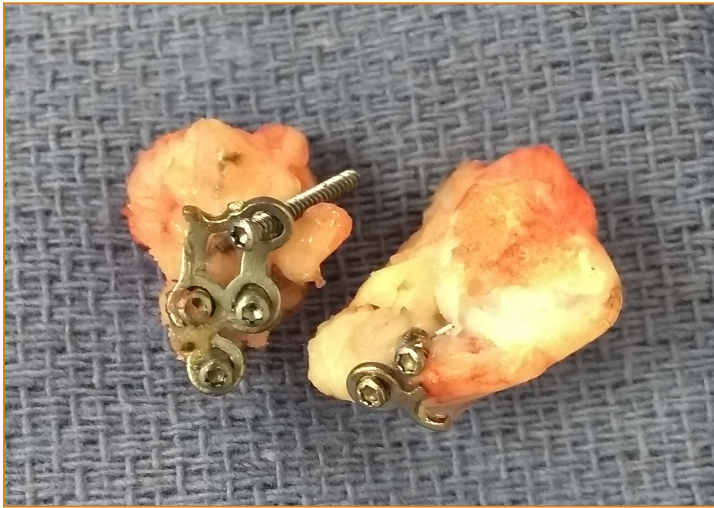

Figure 2: Photograph following excision of the sclerotic scaphoid nonunion with broken plate.

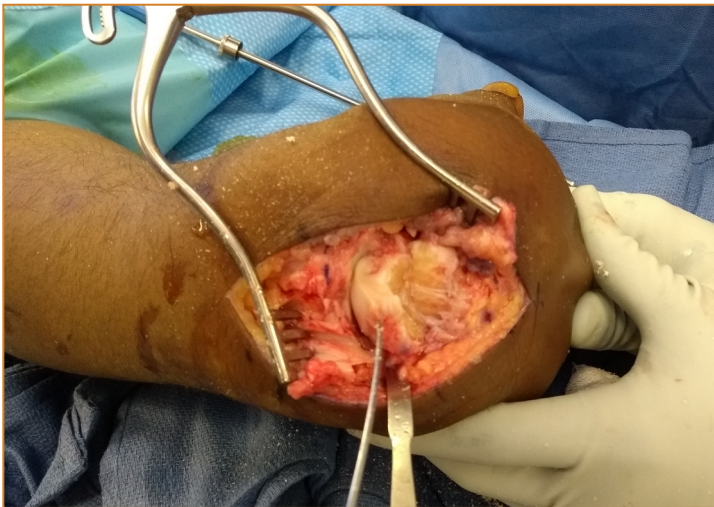


Figure 3: Following excision of the scaphoid, a joystick is placed in a lunate to control rotation. The articular cartilage is removed off the distal aspect of the lunate and triquetrum, and then the proximal aspect of the capitate and hamate.

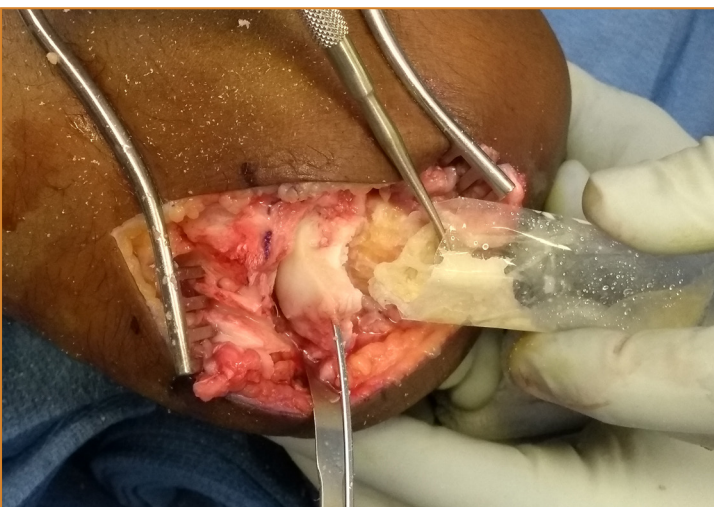


Figure 4: Allograft bone graft is placed at the proposed fusion site between the proximal and distal rows of the carpus.

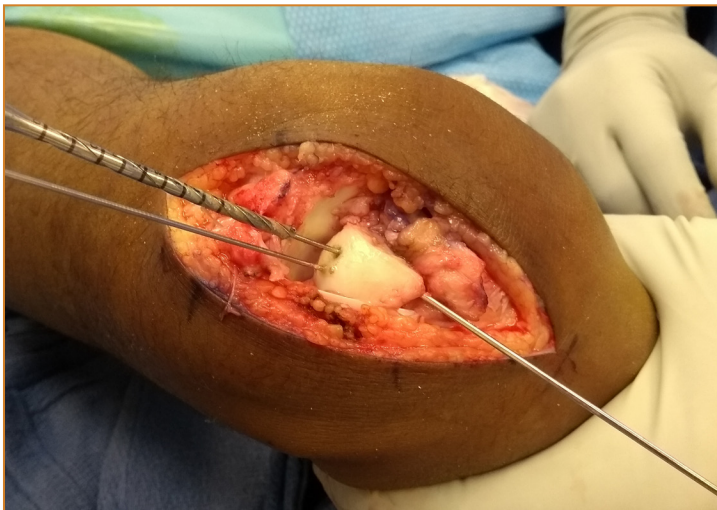


Figure 5: Following provisional stabilization with the guide wires, the lunate and capitate are drilled using the osteocentric cannulated drill.

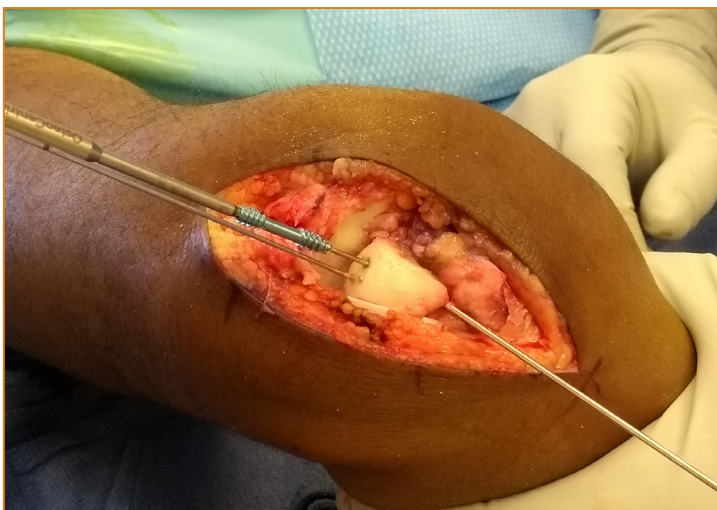


Figure 6: A 3.8 cannulated osteocentric fastener is placed over the guidewire to stabilize the capitate lunata fusion. It is recommended a fastener 4mm shorter than what is measured is used to ensure it is placed well up into the lunate.

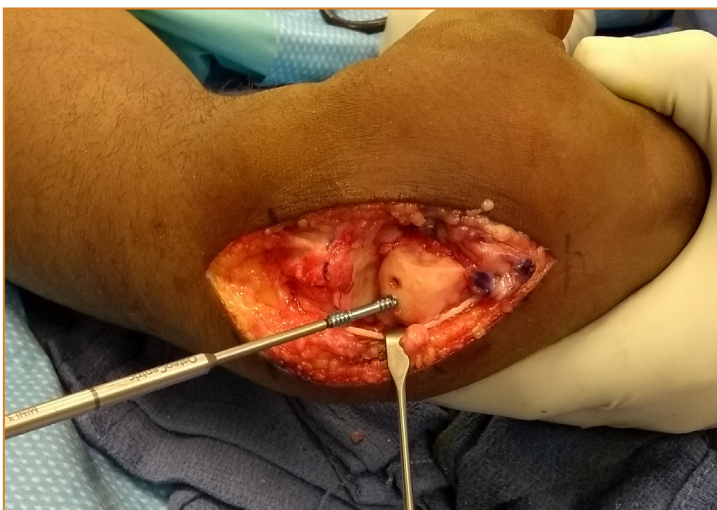

Figure 7: A second osteocentric fastener is placed over the guidewire from the lunate to the hamate.

Two 3.9mm OsteoCentric headless fasteners, 4mm shorter than measured, are then inserted over the guide wires (Fig. 6, 7).

Note, a laser mark is on the screw driver, 2mm proximal, to demonstrate when the screw is inserted 2mm distal into bone.

The third and final 3.9mm OsteoCentric headless fastener is inserted (Fig. 8) and the position is checked using fluoroscopy in both the anterior posterior and lateral planes. Once the ideal placement is confirmed by fluoroscopy, the wound is closed (Fig. 9, 10).

The dorsal capsule is closed only along its most ulnar aspect. The proximal and distal edges are left open to facilitate more wrist flexion. The 2nd and 4th dorsal compartments are closed and the extensor pollicis longus is left free. The patient is splinted for 2 weeks and returns for stitch removal. A removable wrist brace is ordered and the patient is then placed on a physical therapy program for range and motion strengthening.

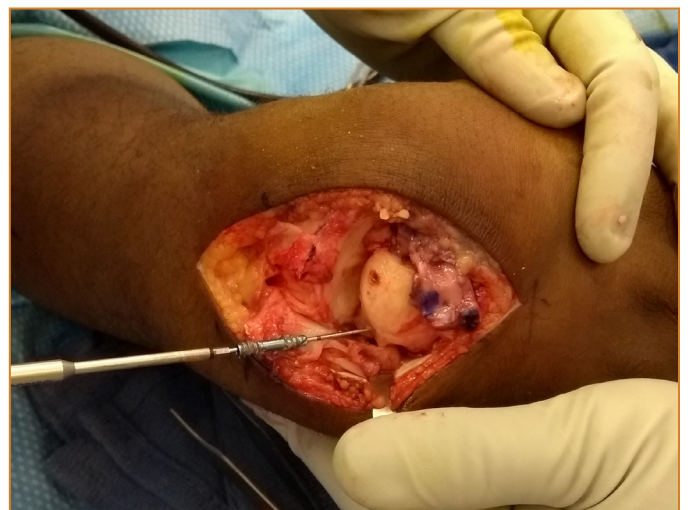


Figure 8: Lastly, the third osteocentric fastener is placed from the triquetrum into the hamate.

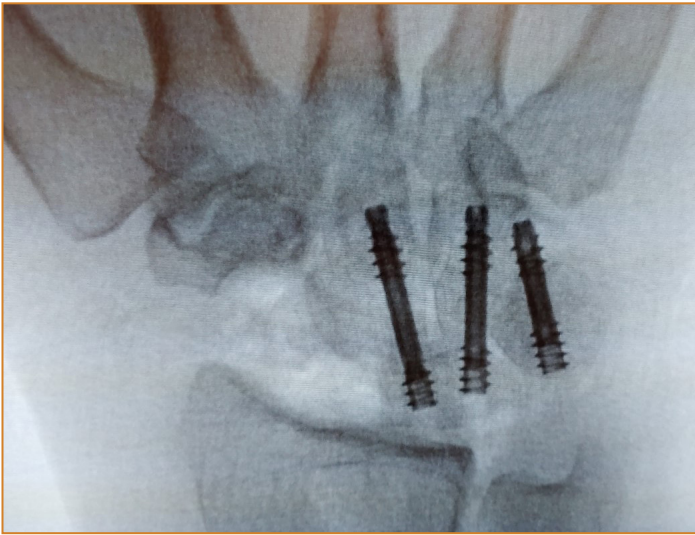


Figure 9: Posterior anterior fluoroscopy demonstrated ideal placement the 3 osteocentric fasteners well up into the carpus.

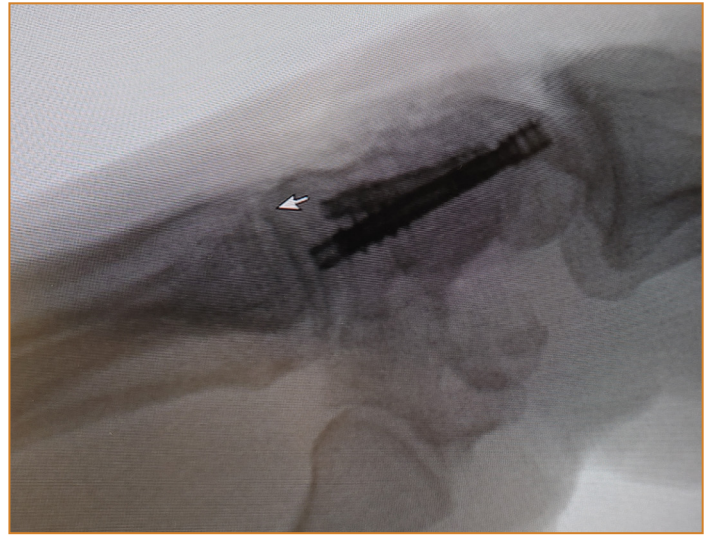


Figure 10: Lateral fluoroscopic view showing the osteocentric fasteners well-centered in the carpus.

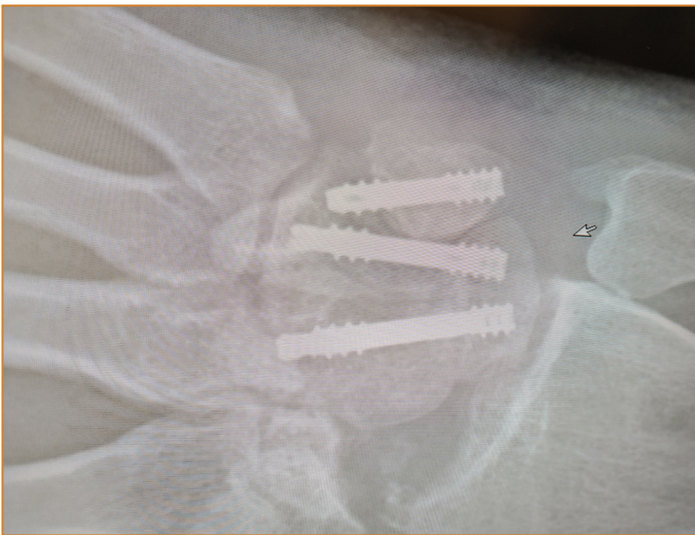


Figure 11: Posterior anterior radiograph at 3 months demonstrating good bony consolidation at the fusion site.

3 Month Follow-Up

Radiographs at the 3 month mark show good bone consolidation of the fusion site (Fig.11). The patient returned to work full duty as a farmer at the 6 week mark and is quite pleased with his results.

Clinical Advantages of UnifiMI®

The OsteoCentric Headless Compression Fasteners provided immediate Mechanical Integration between the implants and bone thus providing a large amount of primary stability throughout the construct, facilitating limited movement and high rates of fusion. Additionally, the cylindrical nature of the compressive implants allowed for flexibility in placement as well as intraoperative adjustment.

These materials contain information about the products that may or may not be available in any particular country or may be available under different trademarks in different countries. The products may be approved or cleared by governmental regulatory organizations for sale or use with different indications or restrictions in different countries. Products may not be approved for use in all countries. Nothing contained on these materials should be construed as a promotion or solicitation for any product or for the use of any product in a particular way which is not authorized under the laws and regulations of the country where the reader is located.



75 West 300 N, Suite 150
 Logan UT, 84321
 Phone: 1-800-969-0639
 info@osteocentric.com
 osteocentric.com