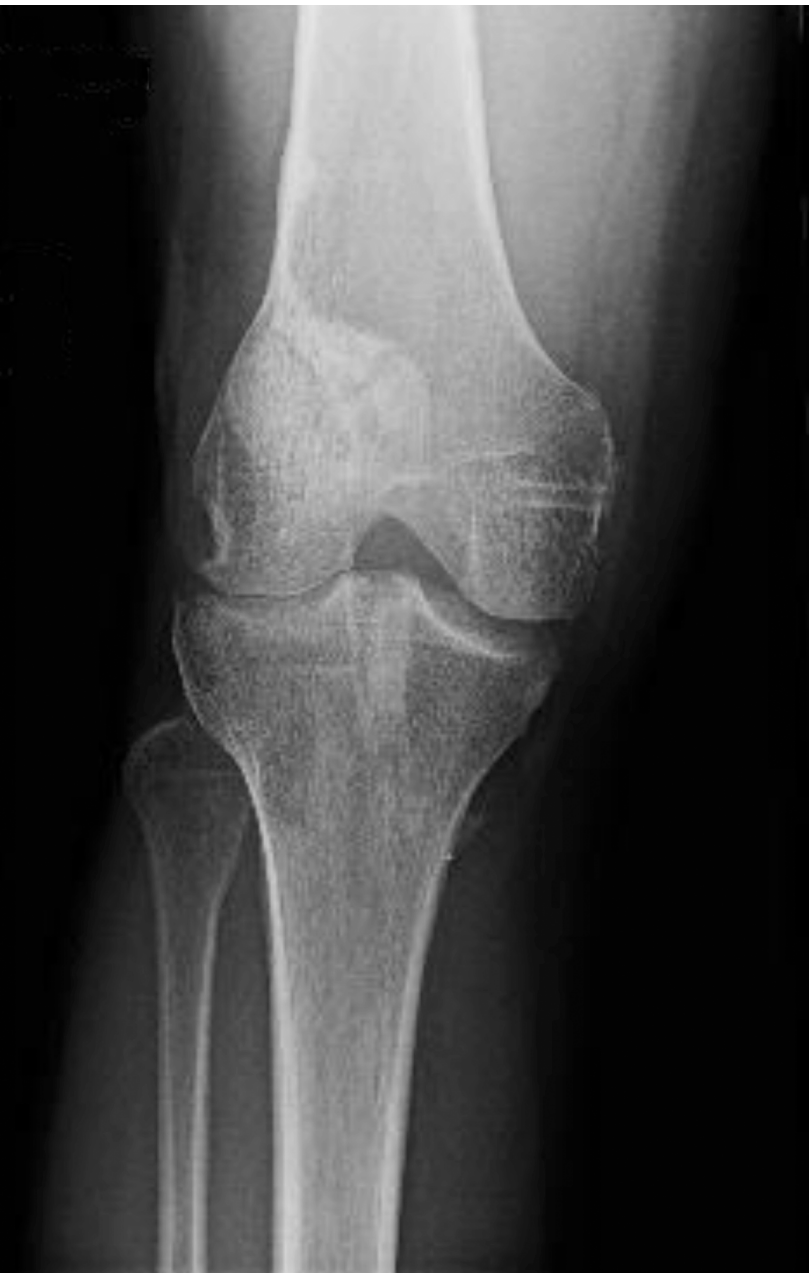

Patella Fracture

UnifiMI[®] Headless Compression System

Case Study | Dr. David Diduch

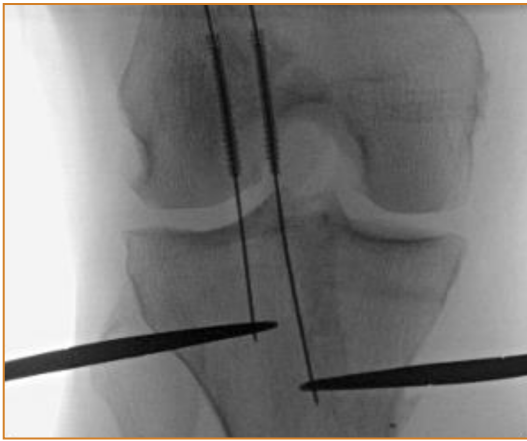


Patient History

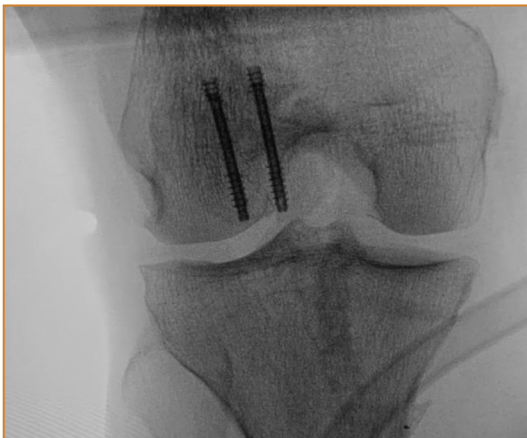A 38 year old, athletically active woman underwent ACL reconstruction with a patella tendon autograft. BTB autograft was chosen given her desire to return to high level skiing and absence of pre-existing patellofemoral pain. Surgery and rehab progressed uneventfully until she had acute pain and an audible crack while doing a wall squat at 3 months post op. Radiographs demonstrated a slightly displaced patella fracture that developed at the top of the patella harvest site. Her donor site had been grafted with autograft bone at the time of surgery and she described no site specific pain suggestive of an imminent stress fracture. Notable in her past history, she had difficulty healing a radial forearm fracture several years prior and underwent three separate bone grafting and stabilization procedures. An extensive laboratory and endocrinology work up failed to identify any conclusive cause for problems with bone healing. Her vitamin D level was in the mid normal range.

Pre-Op Surgical Plan

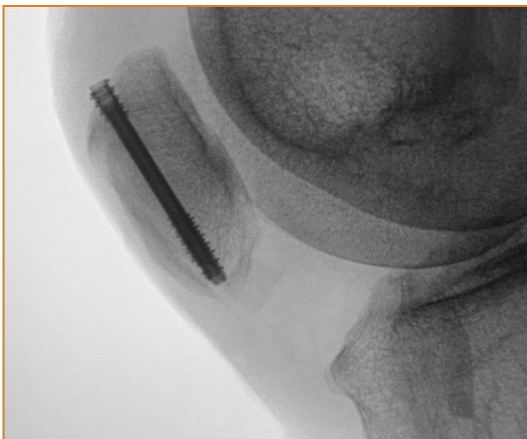Given the slight displacement of the fracture, her desire to return to high level sports, and her history of problematic fracture healing, the decision was made to treat the fracture surgically. Avoiding excessive stripping of the soft tissues and blood supply was important while simultaneously achieving rigid fixation to allow early motion and compression across the fracture site.



Intra-Op



Post-Op



Post-Op

Surgical Procedure

Her previous BTB harvest incision was used to expose the patella. The fracture site itself was not obvious unless the fragments were manually manipulated, consistent with minimal displacement. A small arthrotomy on the lateral side was used to palpate the fracture reduction from the undersurface throughout the case. The OsteoCentric Headless Compression Fasteners were used to achieve rigid fixation and longitudinal compression. Parallel guide wire placement was achieved using the pin guides. Guide wires were placed to achieve optimal spacing for the fracture fragment, starting with the medial wire towards lateral. A temporary central wire was used to “pivot” the parallel guide around to place a third lateral wire more widely spaced and parallel to the first medial wire. The drill was used to create a pilot hole followed by screw placement with alternating compression between each of two 3.9mm headless compression fasteners to optimize fracture compression. Rigid fixation was achieved and confirmed as the knee was ranged.

Follow Up

The patient was treated with partial weight bearing and a hinged knee brace with gradually progressive range of motion allowed over 8 weeks. She healed uneventfully and continued her ACL rehab. She has now resumed all sports without symptoms.

Clinical Advantages of UnifiMI®

The OsteoCentric UnifiMI thread geometry provided ideal bone integration to fix this fracture in a patient who had already demonstrated problematic bone healing. The uniform cylindrical diameter with variable pitch threads was especially helpful since compression and fixation were not dependent on screw depth. The depth of the screw could be optimized to engage the cortex on both ends of the patella without concern if backed up. Also, the engagement of the UnifiMI thread geometry prevented loosening from micro-motion during rehab, which is especially prone to happen with other designs when fixation is dependent on the screw being “tightly down” on insertion with a wider proximal end (or wedge shaped) implant design. The bone purchase negated the need for any additional tension band construct which would have led to soft tissue irritation in front of the knee, although the cannulated design does allow for this.

These materials contain information about the products that may or may not be available in any particular country or may be available under different trademarks in different countries. The products may be approved or cleared by governmental regulatory organizations for sale or use with different indications or restrictions in different countries. Products may not be approved for use in all countries. Nothing contained on these materials should be construed as a promotion or solicitation for any product or for the use of any product in a particular way which is not authorized under the laws and regulations of the country where the reader is located.



75 West 300 N, Suite 150
Logan UT, 84321
Phone: 1-800-969-0639
info@osteocentric.com
osteocentric.com