

Complex Capitellum and Lateral Condyle Multi-Fragment Fracture

UnifiMI® Headless Compression System

Case Study | Dr. William Geissler

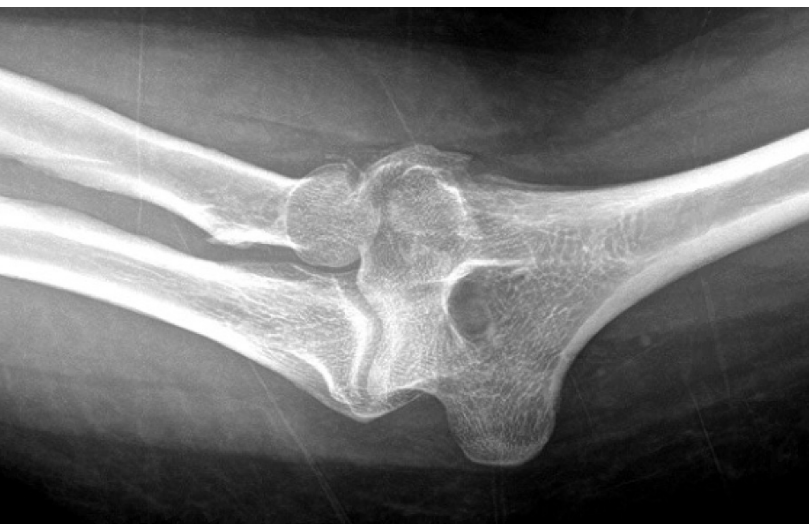

Figure 1: Anterior posterior radiograph showing displaced fracture of the capitellum and lateral condyle.

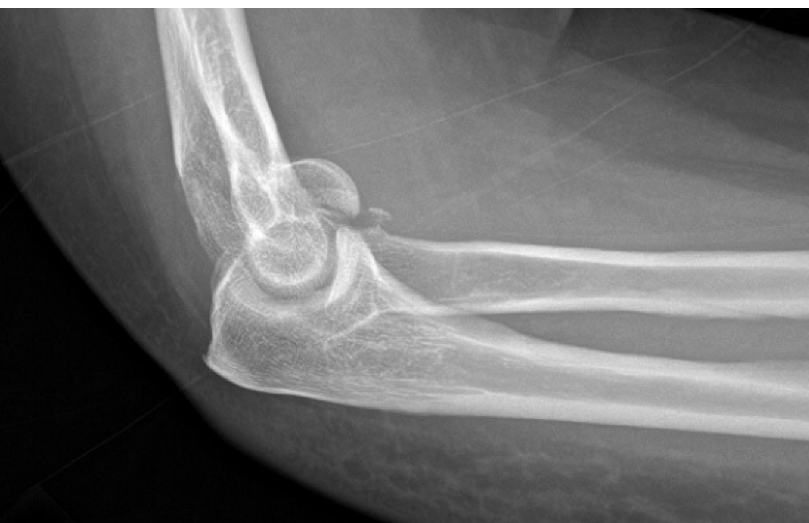

Figure 2: Lateral radiograph demonstrating displaced fractures of the capitellum and lateral condyle. Note the anterior displaced fragment of the capitellum that blocks elbow flexion.

Patient History

The patient is a 36-year old female who presents with right elbow pain. Approximately six weeks prior, she fell on her right outstretched arm sustaining a fracture dislocation to her right elbow. She was reduced at an outside hospital and placed in a splint and now presents for a first clinic visit. She complains of severe pain to the right elbow and lack of motion to the elbow, both with flexion extension and with forearm rotation. She had no complaints of numbness.

On physical examination, well-nourished Caucasian female, well alert and oriented x4. Examination to the right elbow showed mild swelling to the soft spot. She lacked 60° of extension, and had flexion of 90° with a firm bony endpoint. She had no pronation or supination. She was point tender about the lateral column of the elbow with crepitus. The elbow was stable to varus and valgus stress. She was neurovascularly intact.

Anterior posterior and lateral to the right elbow demonstrated displaced fracture fragments of both the capitellum and the lateral condyle (Fig. 1).

Lateral view demonstrated a very displaced capitellum fragment, which was blocking her elbow flexion, also resulting in lack of pronation supination to the forearm (Fig. 2).

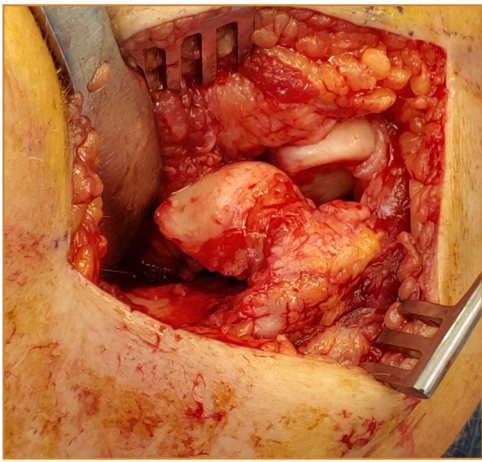


Figure 3: Intraoperative photograph showing displaced fractures of the capitellum and lateral condyle.

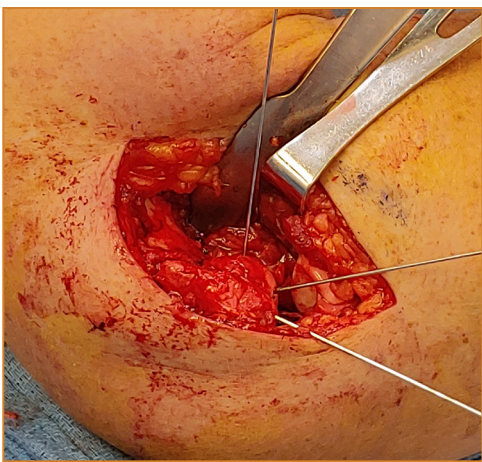


Figure 4: Intraoperative radiograph demonstrating anatomic reduction of both the capitellum and lateral condyle and provisional stabilization with the osteocentric guidewires.

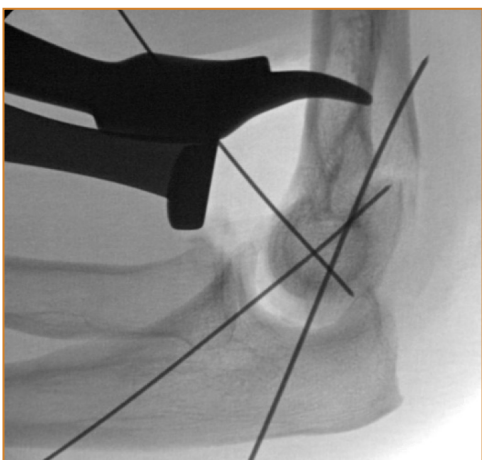


Figure 5: Lateral fluoroscopic view confirming anatomic reduction to both the capitellum and lateral condyle fragment and appropriate position of the osteocentric guidewires.

Treatment

It was determined that she needed an open reduction and internal fixation. A standard straight lateral approach was made to the elbow. Thick skin flaps were elevated, exposing the fascia. The origin of the extensor carpi radialis longus brevis and communis was sharply dissected off the anterior lateral one half of the lateral condyle. Close attention was made not to stray posteriorly, to affect the lateral ulnar humeral complex. The anterior capsule was released from lateral to medial. Releasing the capsule and flexing the elbow allows improved exposure of the elbow without distal dissection, which could potentially involve both the radial posterior interosseous nerve.

The patient had a malunion of a displaced capitellum and lateral condyle fracture (Fig. 3). The early callus was removed off the lateral condyle fracture, and it was opened like a book laterally, to allow anatomic reduction to the capitellum fracture fragment. The lateral condyle fragment was blocking the reduction of the capitellum. The capitellum was anatomic reduced and provisionally stabilized with two osteocentric guidewires for the 2.8mm headless fasteners. Once the capitellum fragment was anatomically reduced, the lateral condyle fragment was reduced back to the distal humerus and provisionally stabilized with the 1.1mm guidewire for the 3.9 mm osteocentric screw (Fig. 4). Two operative fluoroscopic views confirmed anatomic reduction both to the lateral condyle and capitellum fragments, and appropriate position of the OsteoCentric guidewires (Fig. 5).

The lateral condyle fragment was drilled with the cannulated drill, and a 3.9 mm OsteoCentric headless fastener was placed providing very secure fixation to the lateral condyle fragment (Fig. 6, 7, 8).

Next, a 2.8mm OsteoCentric headless fastener was placed providing secure fixation to the capitellum fragment. (Fig. 9, 10, 11, 12).

Following stabilization of both the lateral condyle and capitellum fragments, and the release of the anterior capsule, the patient lacked approximately 10° degrees of full extension and now had full flexion. In addition, she had full pronation supination on the table (Fig. 13, 14).

With the elbow held reduced with the radial head held reduced against the capitellum, and -30° of flexion, the extensor musculature was closed with number 1 vicryl. Following this, the skin was closed.

As the patient presented quite late from injury with a contracture, the patient was placed in a soft tissue dressing. She started physical therapy approximately one week from surgery as felt the stabilization of the fracture fragments was quite secure.

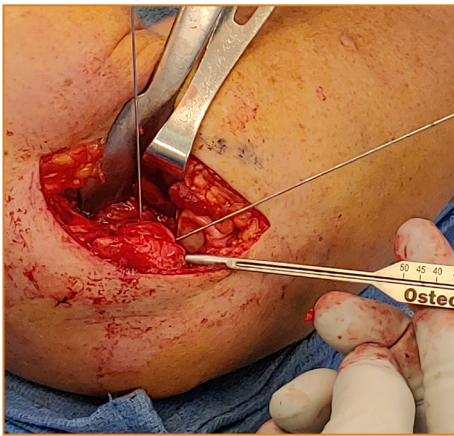


Figure 6: Intraoperative photograph demonstrating measuring for the 3.9mm OsteoCentric headless fastener to support the lateral condyle fragment.

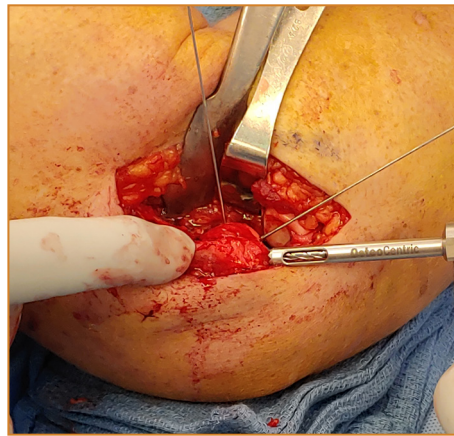


Figure 7: Intraoperative photograph demonstrating the OsteoCentric cannulated drill over the guidewire for the lateral condyle fragment.

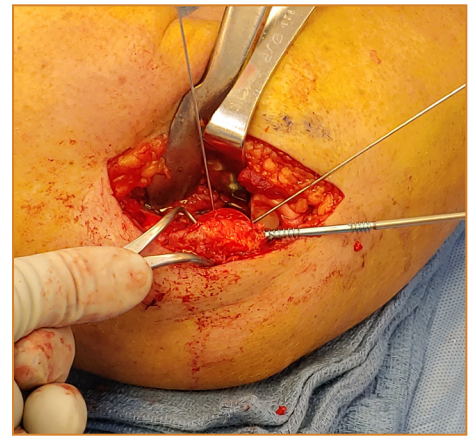


Figure 8: Intraoperative photograph showing a 3.9mm OsteoCentric headless compression fastener being placed over the guidewire to support the lateral condyle fragment.

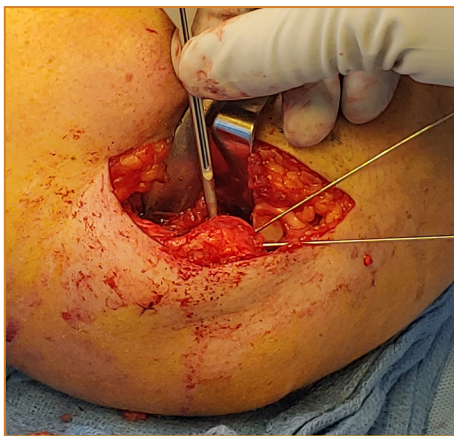


Figure 9: Following stabilization of the lateral condyle fragment, the measuring guide is used to measure the length for the 2.8mm OsteoCentric headless cannulated fastener.

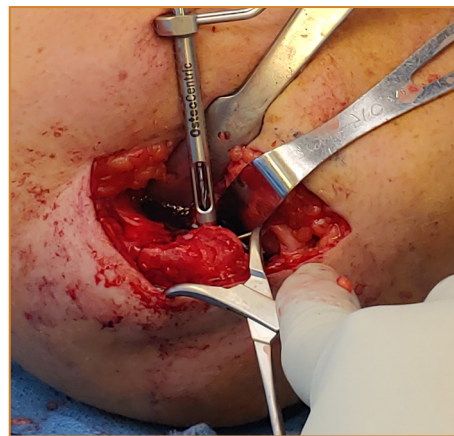


Figure 10: Intraoperative photograph demonstrating the use of the OsteoCentric cannulated drill over the guidewire through the cannula.

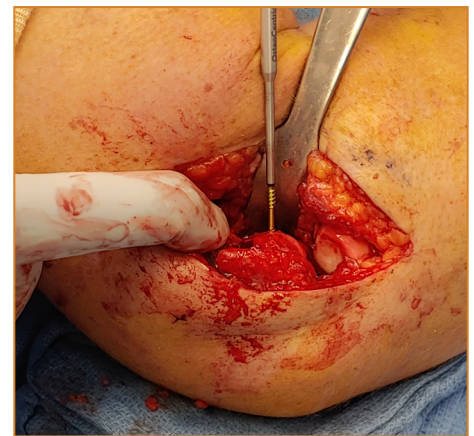


Figure 11: Intraoperative photograph showing placement of the 2.8mm OsteoCentric headless cannulated fastener over the guidewire to support the capitellum fragment.

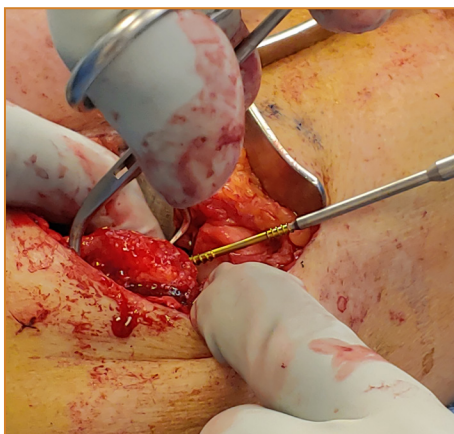


Figure 12: Intraoperative photograph demonstrating the placement of a second 2.9mm osteocentric screw to support and secure the capitellum fragment

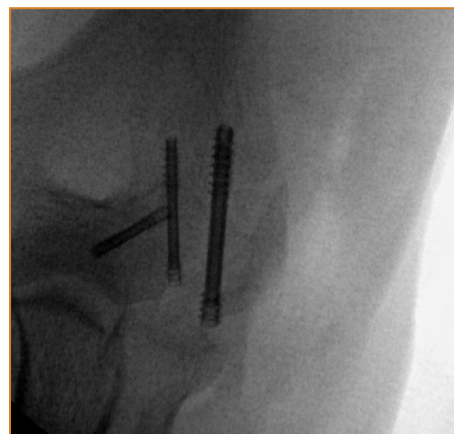

Figure 13: Anterior posterior fluoroscopic view confirming anatomic reduction of the capitellum and the lateral condyle fragment with the OsteoCentric headless compression fasteners. Note the different diameter used for the different fragments.

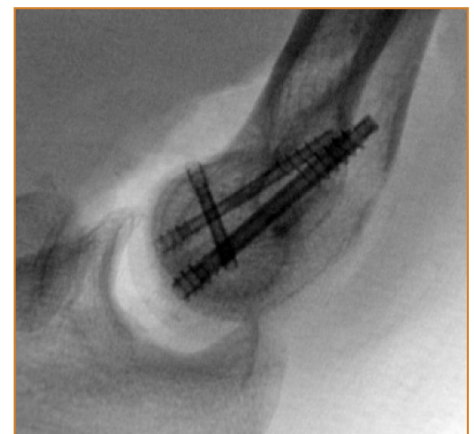


Figure 14: Lateral fluoroscopic view confirming anatomic reduction to the complex intra-articular distal humerus fracture and appropriate length and position of the OsteoCentric headless compression fasteners.

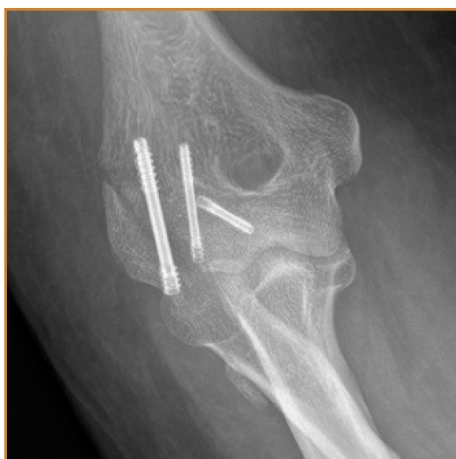

Figure 15: Anterior posterior radiograph demonstrating anatomic reduction to the distal intra-articular humerus fracture with anatomic reduction and bony consolidation.

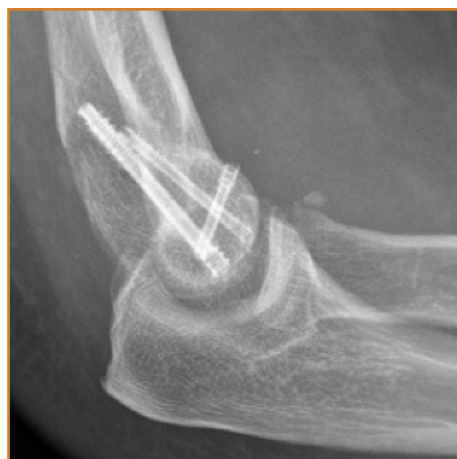

Figure 16: Lateral radiograph confirming anatomic reduction to the intra-articular humerus fracture with anatomic reduction and healing utilizing the two different diameters of the OsteoCentric headless compression fasteners.

Post-Op

Final post-operative range of motion at 3 months, noted she lacked 20° extension and flexed to 140°.

She had 80° of supination, and 80° without crepitus or pain. She reduced and went back to work full duty without restrictions (Fig. 15, 16).

Clinical Advantages of UnifiMI®

1. The OsteoCentric Headless compression fasteners were able to capture and integrate the small bone fragments due in part to the balance of radial inward and radial outward forces in the threads. This is a large advantage versus current devices that only utilize radial outward forces on interfacing bone.
2. The varying diameters (2.8mm & 3.9mm) facilitated optimal sizing for the multiple fractures and fragments within the patient's elbow.
3. Cylindrical design of both size fasteners allowed the implants to be reversed slightly intraoperatively, facilitating ideal implant placement.
4. As noted by the patient, the post-op stability of the construct and limited pain at the surgical site were significant advantages to the PT regimen.

These materials contain information about the products that may or may not be available in any particular country or may be available under different trademarks in different countries. The products may be approved or cleared by governmental regulatory organizations for sale or use with different indications or restrictions in different countries. Products may not be approved for use in all countries. Nothing contained on these materials should be construed as a promotion or solicitation for any product or for the use of any product in a particular way which is not authorized under the laws and regulations of the country where the reader is located.



75 West 300 N, Suite 150
Logan UT, 84321
Phone: 1-800-969-0639
info@osteocentric.com
osteocentric.com