

Patient-Reported and Radiographic Outcomes After Revision Sacroiliac Joint Fusion

JEREMY C. THOMPSON, MD¹; ERICK MARIGI, MD¹; AND WILLIAM W. CROSS, III, MD¹

¹Department of Orthopedic Surgery, Mayo Clinic, Rochester, USA

ABSTRACT

Background: Sacroiliac joint fusion (SIJF) has been established as an effective treatment for sacroiliac joint dysfunction. However, failure necessitating revision has been reported in up to 30% of cases. Little is known regarding outcomes of revision SIJF.

Methods: We retrospectively reviewed all revision SIJF at a single academic center between 2017 and 2020. Revision surgery was performed using the principles of joint decortication, bone grafting, compression, and rigid internal fixation. Outcomes were assessed at 6 months and 1 year after surgery using the Oswestry Disability Index (ODI), Numeric Pain Rating Scale (NPRS), and Single Assessment Numeric Evaluation (SANE) scale. Fusion was assessed using computed tomography at 12 months postoperatively.

Results: Eighteen revision SIJFs in 13 patients were included. The mean age was 55.8 years (range 35–75). Mean body mass index was 27.9 (range 21.7–36.7). Sixty-two percent of the patients were women. The indications for revision were pseudarthrosis without fixation failure in 14 cases (77.8%), hardware failure (loosening) in 3 cases (16.7%), and continued pain after partial fusion in 1 case (5.6%). ODI and NPRS scores demonstrated significant statistical and clinical improvements at all timepoints. Mean (SD) ODI scores improved from 53.8 (19.9) preoperative to 37.5 (19.8) at 6 months and 32.9 (21.7) at 12 months. Improvement in ODI was found in 15 joints (83.3%), and the minimal clinically important difference (MCID) was achieved in 12 joints (66.7%). Mean (SD) NPRS scores improved from 6.5 (1.4) preoperative to 3.2 (2.8) at 6 months and 3.4 (2.6) at 12 months. Improvement in NPRS was also identified in 17 joints (94.4%), and 10 joints (55.6%) achieved MCID for NPRS. Mean (SD) SANE score was 72.0% (30.8) at 6 months and 70.0% (33.8) at 12 months. There were no radiographic lucencies, implant subsidence, or implant fractures at final follow-up. We identified an 88.9% fusion rate with definitive bridging bone across the sacroiliac joint.

Conclusion: Utilizing a principles-based technique of joint decortication, compression, and rigid internal fixation, revision SIJF showed an improvement in patient-reported outcomes as well as high rate of fusion at 12 months. The most common indications for revision SIJF are symptomatic pseudarthrosis and implant loosening. This is the largest series of revision SIJF to date.

Level of Evidence: 4.

Other and Special Categories

Keywords: sacroiliac joint, SI joint, SIJF, sacroiliac joint dysfunction, sacroiliac joint fusion, back pain, decortication, compression, internal fixation, revision

INTRODUCTION

Sacroiliac joint dysfunction (SIJD) is an increasingly recognized source of low back pain. Within patients presenting to a physician for back pain, the sacroiliac joint (SIJ) has been identified as a contributing or predominant factor in many patients.^{1–6} Nonoperative management remains first line; however, SIJ fusion (SIJF) is often pursued for recalcitrant symptoms.^{2,7–12}

SIJF, particularly minimally invasive SIJF, has been demonstrated as a viable treatment option for activity-limiting SIJD. Previous investigations have shown improved patient-reported outcomes, functional improvements, quality of life, and radiographic outcomes after SIJF when compared with nonoperative

management.^{11,13–21} Published reports state revision rates between 0% and 30% depending on the method of fixation and patient-related factors.^{14,19,22–24} However, modern SIJ-specific implant systems have demonstrated low revision rates between 2.1% and 6.7%.^{14,19,25–27} Common mechanisms of failure include implant malposition and symptom recurrence secondary to pseudarthrosis and/or implant failure.

While there have been numerous investigations demonstrating excellent clinical outcomes after primary SIJF, there remains a paucity of data on the outcomes after revision SIJF. Therefore, the purpose of this study is to (1) describe the authors' technique for minimally invasive revision SIJF, (2) determine the patient-reported outcomes after minimally invasive SIJF, and

(3) determine the radiographic outcomes after revision SIJF.

METHODS

Between January 2017 and May 2020, all cases of revision SIJF performed by a single surgeon at a single institution were identified. Patients aged <18 years and those with <12 months of clinical follow-up, revisions for malpositioned instrumentation, or concomitant lumbar procedures at the time of SIJF (including instrumentation removal) were excluded. All patients were implanted with an SIJF system (Integrity SIJ Fusion system with Blade-X Technology, OsteoCentric Technologies, Logan, UT) that utilizes the surgical principles of aggressive joint decortication, percutaneous autografting, compression across the SIJ with rigid internal fixation, and a fenestrated design allowing ingrowth across the SIJ and through the implant. All patients were followed clinically for at least 12 months postoperatively with clinical and radiographic evaluation at 6 and 12 months. Pelvis computed tomography (CT) images were routinely obtained at 12 months postoperatively to assess fusion. Patients filled validated patient-reported outcome measurements: the Oswestry Disability Index (ODI), Numeric Pain Rating Scale (NPRS), and Single Assessment Numeric Evaluation (SANE) Scale. The minimal clinically important differences (MCIDs) used for the ODI and NPRS were 10 and 2, respectively.²⁸

Arthrodesis was assessed via CT image and confirmed under the following criteria: (1) bridging fusion mass across the SIJ in >2 consecutive 2-mm cuts, (2) lack of peri-implant halo, and (3) lack of hardware breakage. Fusion assessment was classified using a previously described graded scale: Grade 1, no evidence of bone growth across the SIJ; Grade 2, bone growth evident but no definitive bridging bone identified; and Grade 3, bone growth clearly demonstrated bridging the SIJ.²⁹ Last, all CT images were critically reviewed by the authors and a musculoskeletal radiologist for implant loosening, subsidence on the iliac or sacral sides of the SIJ, or neural foramen penetration.

Patient Evaluation

Our evaluation for pain after SIJF includes a patient history, physical examination, radiographic evaluation including pelvis CT without contrast, and, in most cases, diagnostic injection. The details regarding preoperative symptoms, date of primary SIJF, postoperative symptoms, and current presenting symptoms were obtained. Patients were candidates for revision SIJF if specific

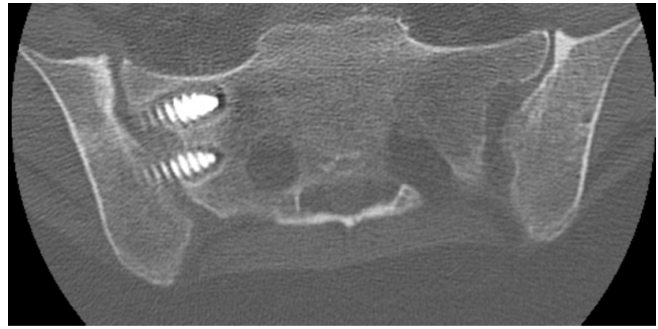


Figure 1. Loosening of sacroiliac joint instrumentation with gross halo and no evidence of bridging bone through the sacroiliac joint.

criteria were met. First, the patient must have signs and symptoms consistent with SIJ-mediated pain. Common historical signs and symptoms include pain located over the buttocks with radiation to the posterior thigh as well as recurrence of symptoms after initial postoperative resolution. Patients must also have ≥ 3 physical examination maneuvers consistent with SIJ-mediated pain. Physical examination maneuvers include pain with direct posterior superior iliac spine (PSIS) palpation, PSIS distraction, flexion abduction external rotation (FABER) test, Mayo SIJ test (FABER/PSIS distraction combined test), and Gaenslen test.^{2,3,30} Second, patients must have radiographic evidence of failure of previous SIJF instrumentation or pseudarthrosis. Hardware failure included broken instrumentation and/or hardware loosening (Figure 1). The criteria as suggested by Fogel et al to define pseudarthrosis were used. This is described as (1) absence of bridging bone across the joint surface in 2 consecutive slices on thin-cut CT, and/or (2) evidence of instrumentation breakage or migration³¹ (Figures 2–3). Third, if pain was not deemed to be from implant malposition, patients underwent diagnostic, local anesthetic-only image-guided (CT or fluoroscopy) injection of the SIJ. Overall, patients must have radiographic and physical examination findings that correlate with the patient's presenting pain syndrome.

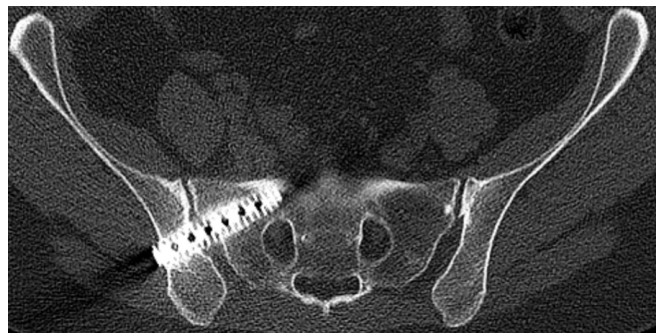


Figure 2. Pseudarthrosis without bridging bone through the sacroiliac joint without instrumentation loosening.

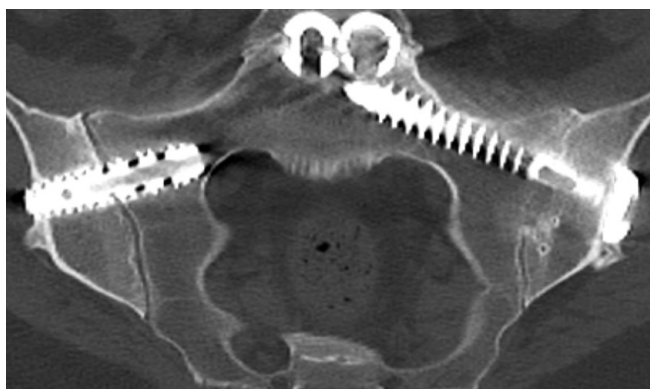

Figure 3. Sacroiliac joint (SIJ) fusion with author's described technique (left SIJ). Right SIJ shows pseudarthrosis without instrumentation failure.

Surgical Technique

Minimally invasive revision SIJF was performed in the prone position under general anesthesia. The patient's previous incision was reopened if amenable to the revision approach, and intraoperative fluoroscopy was used to identify the previous instrumentation. We typically used a 0.062-inch Kirschner wire (K-wire) to cannulate the previous instrumentation. If the implant company and model were known preoperatively, an instrumentation removal set from the company was used to assist with removal. Otherwise, a standard hardware removal set with cannulated screwdrivers and/or trephines was used for implant removal. If the implant was unable to be easily cannulated, a tubular retractor system (MAST Quadrant System, Medtronic, Minneapolis, MN) was used to expose the previous instrumentation for direct visualization and implant removal. It was not uncommon that the previous instrumentation was grossly loose in the setting of pseudarthroses or instrumentation failure. Common findings were ilium ingrowth and a loose sacral implant.

Once the previous instrumentation was removed, the minimally invasive SIJ fusion was used. Utilizing inlet, outlet, and lateral fluoroscopy, a 3.2-mm K-wire was placed across the SIJ in the intended trajectory and position of the implant. The inner and outer tables of the ilium as well as the sacral aspect of the SIJ were drilled with a 12-mm-deep fluted drill. A deployable, rigid blade was then used to aggressively decorticate the SIJ. The fusion zone was then irrigated, and joint debris suctioned out, and a combination of autograft and bone graft extender was placed percutaneously into the void. The autograft was obtained from the 12-mm-deep fluted drill with an average yield of 1 to 4 cc. Bone graft extenders typically included 5 cc of demineralized bone matrix (AlloSync, Arthrex Inc, Naples, FL, USA) and 1.05-mg recombinant bone morphogenetic

protein-2 (Infuse, Medtronic, Minneapolis, MN, USA). The bone morphogenetic protein-2 was used off-label and only after patient consent. The 3.2-mm K-wire was then replaced in the intended screw trajectory and the fusion implant placed over this wire. Every effort was utilized to have the implant engage the dense bone in the vertebral body of the S1 or S2 sacral segment (most typically S1), depending on any elements of sacral dysmorphism.³²⁻³⁴ The implant utilized a 10-mm or 12-mm lag screw design, and compression across the SIJ was confirmed with fluoroscopic imaging. The antirotation screw was then placed distal to the implant in a trajectory parallel to the implant, stopping just short of the S1 foramen. Final implant seating and adequate compression across the SIJ were verified by using an anterior-posterior view with a 20° to 40° tilt to match the slant of the pelvic outer table.

Statistical Measures

The statistical analysis was performed utilizing BlueSky 7.4.0 software (BlueSky Statistics Inc., Chicago, IL, USA). Continuous variables were reported as means with ranges or SDs. Group numeric values were compared utilizing the Student *t* test for parametric values and the Kruskal-Wallis for nonparametric distributions. Categorical variables were assessed with the χ^2 test, or the Fisher's exact test, given low counts of certain comparisons. For all data points, statistical significance was achieved when the *P* value was less than 0.05.

RESULTS

Demographics

A total of 21 revision SIJFs performed in 15 patients were included in the study period. Three joints in 2 patients were excluded from the sample. One patient underwent concomitant lumbar instrumentation removal at the time of revision bilateral SIJF, and 1 patient underwent revision for instrumentation malposition, causing neurologic compression. There was an additional patient who developed a pseudarthrosis whose SIJF implant did not cross the SIJ. This failure was classified as a pseudarthrosis and not an implant malposition, since the primary reason for revision was his painful pseudarthrosis, not neurologic compression from the malpositioned implant. Thus, our analysis included 18 revision SIJFs. There were 5 bilateral revision SIJFs, 3 of whom underwent simultaneous, single-anesthetic bilateral revision SIJF. The mean age was 55.8 years (range 35–78) (Table 1). Mean body mass

Table 1. Patient demographics.

Demographic	N = 13
Sacroiliac fusions, <i>n</i>	18
Bilateral	5
Age, y, mean (SD)	55.8 (35–78)
Body mass index, mean (SD)	27.9 (21.7–36.7)
Sex, <i>n</i> (%)	
Men	5 (38%)
Women	8 (62%)
Prior spine surgery, <i>n/N</i> (%)	7/13 (54%)
Lumbar fusion, <i>n/N</i> (%)	6/7 (86%)
Lumbar decompression, <i>n/N</i> (%)	1/7 (14%)

index was 27.9 (range 21.7–36.7). Sixty-two percent of the patients were women. Seven patients had previous spine surgery, 6 of whom had previous lumbar fusion. All patients were nonsmokers for at least 6 weeks prior to surgery. Two patients had previously undergone a revision SIJF prior to this reported revision.

Indications for Revision

The indications for revision surgery were pseudarthrosis without fixation failure in 14 joints (77.8%), hardware failure (loosening) in 3 joints (16.7%), and continued pain after partial fusion in 1 joint (5.6%) (Table 2). The interval between primary and revision surgery was 27.6 months (range 5–106 months). Of those who underwent revision for pseudarthrosis without fixation failure, with fixation failure, and partial fusion, the interval was 24.5 months (range 5–85 months), 15.7 months (range 5–29 months), and 106 months, respectively.

Patient-Reported Outcomes

ODI and NPRS scores demonstrated significant statistical and clinical improvements at all postoperative timepoints (Figures 4 and 5). Mean (SD, 95% CI) ODI scores improved from 53.8 (19.9, 95% CI 44.6–63.0) preoperatively to 37.5 (19.8, 95% CI 28.1–47.0) at 6 months and 32.9 (22.7, 95% CI 22.2–43.7) at 12 months ($P < 0.001$). Improvement in ODI was found in 15 cases (83.3%), and the MCID was achieved in 12 cases (66.7%). Mean (SD, 95% CI) NPRS scores improved from 6.5 (1.38, 95% CI 0.6–7.1) preoperatively to 3.2 (2.8, 95% CI 1.28–4.45) at 6 months and 3.4 (2.6, 95% CI 1.2–4.6) at 12 months ($P < 0.001$). Improvement in NPRS was also identified in 17 cases (94.4%), and

Table 2. Indications for revision surgery.

Indication, <i>n</i> (%)	N = 18
Pseudarthrosis without fixation failure	14 (77.8%)
Fixation failure	3 (16.7%)
Partial fusion	1 (5.6%)

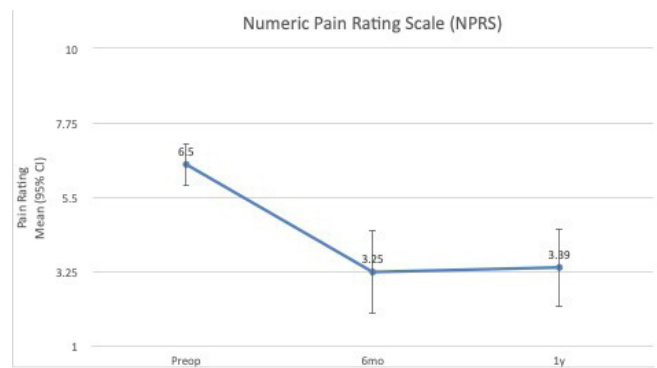


Figure 4. Numeric Pain Rating Scale scores; $P < 0.001$. Abbreviation: Preop, preoperative.

10 cases (55.6%) achieved MCID for NPRS. Mean SANE (SD) was 72.0% (30.82) at 6 months and 70.0% (33.83) at 12 months. There was no association between patients with previous spine surgery or indication for revision and achieving MCID in ODI and NPRS.

Radiographic Outcomes

Postoperative CT image at 12 months was available for 17/18 (94%) of cases. There were no radiographic lucencies, implant subsidences, or implant fractures that occurred at 12 months postoperative (Table 3). We identified an 88.9% fusion rate with definitive bridging bone across the SIJ (Figures 3 and 6). A single case (5.6%) demonstrated bone growth without definitive bridging fusion mass. There were no cases of absent bone growth. The authors and attending radiologist demonstrated agreement on evaluation of fusion status on all cases.

Complications

There were no serious procedure-related adverse events. There were no revision surgeries in the cohort.

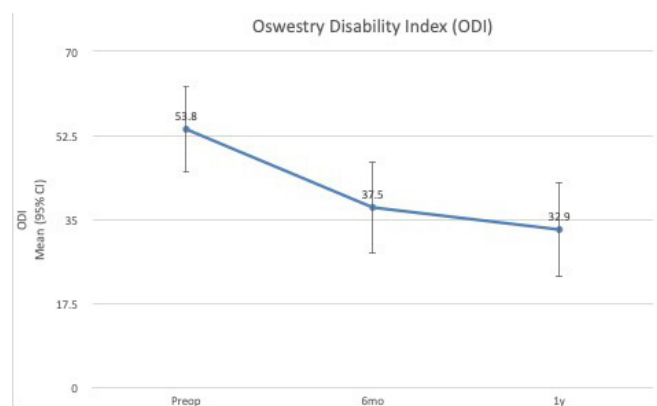


Figure 5. Oswestry Disability Index scores; $P < 0.001$. Abbreviation: Preop, preoperative.

Table 3. CT fusion grade.

Grade	Definition	N (%)
1	Absent bridging bone/fusion mass	0 (0%)
2	Bone growth present <i>without</i> definitive bridging	1 (5.6%)
3	Definitive bridging bone across sacroiliac joint	1 (88.9%)
NA	-	1 (5.6%)

Abbreviations: CT, computed tomography; NA, not available.

DISCUSSION

This review represents the largest clinical series of revision SIJF to date and demonstrated clinically and statistically significant improvement in patient-reported outcomes and an 88.9% rate of fusion in 18 SIJs 1 year after revision SIJF. Our surgical principles emphasize joint decortication, compressions, and rigid internal fixation. Patients experienced a 42.2% improvement in mean ODI and a 47.8% improvement in mean NPRS. Patients reported a mean SANE score of about 70%. In other words, patients reported 70% improvement of their SIJ-related pain at 1 year after surgery. Eighty-three percent of patients reported improvement in ODI, and 66.7% met the MCID for ODI.²⁸ Likewise, 94.4% of patients reported improvement in NPRS, with 55.6% meeting MCID for NPRS. The most common indication for revision was pseudarthrosis without fixation failure (77.8%) followed by fixation failure (16.7%) and partial fusion with recurrent pain (5.6%). There were no surgical complications of infection, hematoma, thrombosis, implant malposition, implant failure, or revision surgery within the study period.

Although there are randomized controlled trials and retrospective studies observing outcomes after primary SIJF, there are few previous studies reporting the outcomes of revision SIJF. At the time of this study, data regarding revision SIJF were limited to case reports, technique guides, and cadaver biomechanical reports,

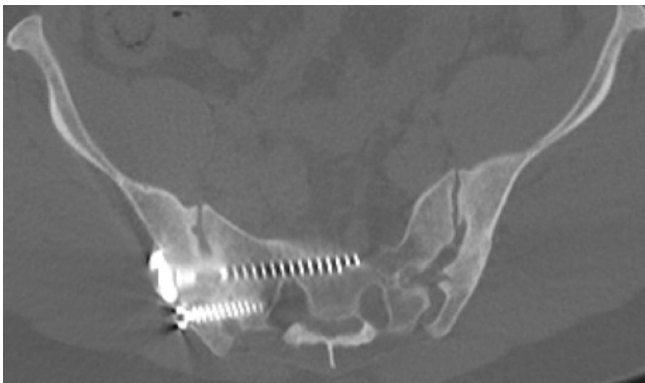


Figure 6. Sacroiliac joint fusion with definitive bridging bone through the sacroiliac joint.

with the current largest published series regarding outcomes of revision SIJF is 7 cases. Cognetti et al reported on their series of 5 patients who underwent revision SIJF utilizing a minimally invasive approach.²⁷ The indications for revision were implant malposition with lumbar radiculopathy in 1 patient and pseudarthroses with recurrence of pain in the remaining 4 patients. All patients reported satisfaction and pain improvement after the revision procedure. However, 2 patients reported low back pain that was dissimilar from their presenting SIJ-mediated pain. The authors did not obtain patient-reported outcomes but did note “interosseus bridging” on follow-up CT 2 years after surgery in all patients. MenMuir et al published a series of 4 patients who underwent minimally invasive revision SIJF with a technique that utilized decortication and a threaded implant.²⁶ All patients were revised for loss of fixation and continued pain. The authors reported that all patients had resolution of prerevision symptoms. However, patient-reported and functional outcomes were not measured, and only 1 patient obtained a postoperative CT image, confirming fusion. Sayed et al reported on the use of a minimally invasive posterior approach SIJF device (Linq [PainTeq, Tampa, FL, USA]) as a salvage of failed lateral SIJF in 7 patients.³⁵ The authors reported a mean NPRS improvement from 8 to 2 at final follow-up. Details regarding the indication for surgery were not included, and there was no formal evaluation of radiographic fusion prior to or after the revision procedure. Additionally, the follow-up was limited to 10 months. However, the authors did report on a single patient who showed postoperative bridging fusion mass after revision procedure. A potential confounder in this study is that 5 of the 8 authors are paid consultants for the device discussed.

There is a growing body of literature describing the outcomes after primary SIJF. While studies generally report good outcomes, there is a subset of patients who experience continued, recurrent, or new pain after SIJF. This postoperative pain may be related to an incomplete diagnosis, implant malposition, surgical technique, and/or lack of fusion. Revision surgery has been reported to be relatively rare but dependent on surgical technique. In a retrospective review of 312 patients treated with multiple 7.2-mm screw fixation vs triangular titanium implants, Spain et al found a 4-year cumulative revision rate of 30.8% after fixation with screws alone and 5.7% after fusion with triangular titanium implants. It should be noted that screw group had no joint preparation prior to screw placement.²⁴ The indication for revision was implant loosening in the screw fixation

group and implant malposition in the triangular implant group. Mitchell et al described an increased rate of implant loosening when implants only have purchase in the sacral alar bone compared with implants with purchase in the more dense sacral body.³⁶ Claus et al reported a 6.1% revision rate after SIJF using threaded implants secondary to implant loosening, pseudarthrosis, and persistent pain. Once again, there was no joint preparation in the screw group.³⁷ Review studies have reported overall revision rates at approximately 3.8% at 2 years.³⁸ The most common indication for revision was pseudarthrosis without fixation failure (71.4%) followed by fixation failure (14%), implant malposition (9.5%), and partial fusion with recurrent pain (4.7%). Patients under each indication for revision experienced continued, recurrent, or new pain after primary SIJF, positive SIJ physical examination maneuvers, and positive response to diagnostic SIJ injection. Thus, we identified that the patients' pain continued to originate from the SIJ, particularly in the group with lack of bridging bone but no evidence of implant loosening.

Controversy and tremendous variability exist regarding the technique and method of fixation for SIJF. Growing acceptance and advances in the treatment of SIJD has led to the development of a wide variety of SIJF devices with various techniques.³⁹ Specific controversies include lateral vs posterior approach, transfixion vs arthrodesis, fixation into the sacral alar vs sacral body, and the use of decortication. The author's preference is for a technique that emphasizes the arbeitsgemeinschaft für osteosynthesefragen bone healing and fusion principles of (1) bone surface preparation, (2) bone grafting, (3) compression through the fusion surfaces, and (4) rigid internal fixation.⁴⁰⁻⁴⁴ It is also the author's preference to perform SIJF through a soft-tissue-friendly minimally invasive lateral approach and with implants that engage the denser midline sacral body opposed to the less dense sacral alar bone.

Fusion was identified in 88.9% of joints using the aforementioned principles. These fusion results compare positively to what is published in the primary SIJF literature, even with a technique that incorporates joint decortication. Duhon et al and Dengler et al reported bridging bone across the SIJ in 25% and 35% of patients at 12 months after primary SIJF using triangular titanium implants.^{45,46} Conversely, Kucharzyk et al, Cross et al, Kube et al, and Abassi et al reported 68.7%, 78.9%, 88.2%, and 73.7% fusion rates at 12 months, respectively, utilizing a technique that included SIJ decortication and a threaded implant.^{29,47-49} Thus, it is the author's preference to approach the SIJF

procedure utilizing joint decortication, compression, and rigid internal fixation through a soft-tissue-friendly minimally invasive lateral approach.

There are several limitations of this study. First, this is a retrospective, single-institution and single-surgeon case series. As such, there are some nuances to patient selection, and bias may have influenced our outcomes. Second, there is a lack of a control group to other SIJF techniques/implants and conservative management. Third, there is a relatively small sample size, which may lead to underpowered results. However, this is the largest series on revision SIJF yet reported. We attempted to minimize patient selection variability by excluding patients with concomitant spinal procedures and those revised for implant malposition, causing neurologic compression. It is important to note that our study still demonstrated statistical improvement of all reported patient-reported outcome measurements; however, there could be additional findings that remain undetected. Fourth, given the single surgeon and tertiary referral nature of the practice, the results are likely influenced by our singular study protocols, evaluation, and management, which may not be as generalizable to other practice types.

CONCLUSION

Revision SIJF, utilizing a principles-based technique of (1) joint decortication, (2) bone grafting, (3) compression, and (4) rigid internal fixation, shows improvement in patient-reported outcomes as well as high rate of fusion at 12 months. The most common indications for revision SIJF are symptomatic pseudarthrosis and implant loosening.

REFERENCES

1. Booth J, Morris S. The sacroiliac joint-victim or culprit. *Best Pract Res Clin Rheumatol*. 2019;33(1):88-101. doi:10.1016/j.berh.2019.01.016
2. Cahueque M, Ardebol J, Armas J, Azmitia E. Sacroiliac pain: diagnosis and treatment. *Acta Ortop Mex*. 2021;35(1):85-91. doi:10.35366/100937
3. Gartenberg A, Nessim A, Cho W. Sacroiliac joint dysfunction: pathophysiology, diagnosis, and treatment. *Eur Spine J*. 2021;30(10):2936-2943. doi:10.1007/s00586-021-06927-9
4. Lee YC, Lee R, Harman C. The incidence of new onset sacroiliac joint pain following lumbar fusion. *J Spine Surg*. 2019;5(3):310-314. doi:10.21037/jss.2019.09.05
5. Sembrano JN, Polly DW. How often is low back pain not coming from the back? *Spine (Phila Pa 1976)*. 2009;34(1):E27-E32. doi:10.1097/BRS.0b013e31818b8882
6. Wieczorek A, Campau E, Pionk E, Gabriel-Champine ME, Ríos-Bedoya CF. A closer look into the association between

- the sacroiliac joint and low back pain. *Spartan Med Res J*. 2021;6(1):21971. doi:10.51894/001c.21971
7. Ballatori AM, Shahrestani S, Chen XT, Ton A, Wang JC, Buser Z. Propensity-matched analysis of 1062 patients following minimally invasive versus open sacroiliac joint fusion. *Clin Spine Surg*. 2021;34(8):E477–E482. doi:10.1097/BSD.0000000000001244
 8. Lingutla KK, Pollock R, Ahuja S. Sacroiliac joint fusion for low back pain: a systematic review and meta-analysis. *Eur Spine J*. 2016;25(6):1924–1931. doi:10.1007/s00586-016-4490-8
 9. Martin CT, Haase L, Lender PA, Polly DW. Minimally invasive sacroiliac joint fusion: the current evidence. *Int J Spine Surg*. 2020;14(Suppl 1):20–29. doi:10.14444/6072
 10. Oren NC, Ali S, Mok J, Lu ZF, Lee SK. Sacroiliac joint injections with the guidance of three-dimensional cone beam computed tomography (3D-CBCT) and fluoroscopy fusion. *J Neurointerv Surg*. 2021;13(2):191–195. doi:10.1136/neurintsurg-2020-016212
 11. Yson SC, Sembrano JN, Polly DW. Sacroiliac joint fusion: approaches and recent outcomes. *PMR*. 2019;11 Suppl 1:S114–S117. doi:10.1002/pmrj.12198
 12. Zaidi HA, Montoure AJ, Dickman CA. Surgical and clinical efficacy of sacroiliac joint fusion: a systematic review of the literature. *J Neurosurg Spine*. 2015;23(1):59–66. doi:10.3171/2014.10.SPINE14516
 13. Chen L-Y, Liang H-D, Qin Q-N, et al. Sacroiliac joint fusion vs conservative management for chronic low back pain attributed to the sacroiliac joint: a protocol for systematic review and meta analysis. *Medicine (Baltimore)*. 2020;99(46):e23223. doi:10.1097/MD.0000000000002323
 14. Cleveland AW, Nhan DT, Akiyama M, Kleck CJ, Noshchenko A, Patel VV. Mini-open sacroiliac joint fusion with direct bone grafting and minimally invasive fixation using intraoperative navigation. *J Spine Surg*. 2019;5(1):31–37. doi:10.21037/jss.2019.01.04
 15. Darr E, Meyer SC, Whang PG, et al. Long-term prospective outcomes after minimally invasive trans-iliac sacroiliac joint fusion using triangular titanium implants. *Med Devices (Auckl)*. 2018;11:113–121. doi:10.2147/MDER.S160989
 16. Duhon BS, Bitan F, Lockstadt H, et al. Triangular titanium implants for minimally invasive sacroiliac joint fusion: 2-year follow-up from a prospective multicenter trial. *Int J Spine Surg*. 2016;10:13. doi:10.14444/3013
 17. Ledonio CGT, Polly DW, Swiontkowski MF. Minimally invasive versus open sacroiliac joint fusion: are they similarly safe and effective? *Clin Orthop Relat Res*. 2014;472(6):1831–1838. doi:10.1007/s11999-014-3499-8
 18. Ledonio CG, Polly DW, Swiontkowski MF, Cummings JT. Comparative effectiveness of open versus minimally invasive sacroiliac joint fusion. *Med Devices (Auckl)*. 2014;7:187–193. doi:10.2147/MDER.S60370
 19. Shamrock AG, Patel A, Alam M, Shamrock KH, Al Maaieh M. The safety profile of percutaneous minimally invasive sacroiliac joint fusion. *Global Spine J*. 2019;9(8):874–880. doi:10.1177/2192568218816981
 20. Smith AG, Capobianco R, Cher D, et al. Open versus minimally invasive sacroiliac joint fusion: a multi-center comparison of perioperative measures and clinical outcomes. *Ann Surg Innov Res*. 2013;7(1):14. doi:10.1186/1750-1164-7-14
 21. Whang PG, Darr E, Meyer SC, et al. Long-term prospective clinical and radiographic outcomes after minimally invasive lateral transiliac sacroiliac joint fusion using triangular titanium implants. *Med Devices (Auckl)*. 2019;12:411–422. doi:10.2147/MDER.S219862
 22. Cher DJ, Reckling WC, Capobianco RA. Implant survivorship analysis after minimally invasive sacroiliac joint fusion using the ifuse implant system (®). *Med Devices (Auckl)*. 2015;8:485–492. doi:10.2147/MDER.S94885
 23. Miller LE, Block JE. Minimally invasive arthrodesis for chronic sacroiliac joint dysfunction using the symmetry SI joint fusion system. *Med Devices (Auckl)*. 2014;7:125–130. doi:10.2147/MDER.S63575
 24. Spain K, Holt T. Surgical revision after sacroiliac joint fixation or fusion. *Int J Spine Surg*. 2017;11(1):5:5. doi:10.14444/4005
 25. Heiney J, Capobianco R, Cher D. A systematic review of minimally invasive sacroiliac joint fusion utilizing a lateral transarticular technique. *Int J Spine Surg*. 2015;9:40. doi:10.14444/2040
 26. MenMuir B, Fielding LC. Revision of minimally invasive sacroiliac joint fixation: technical considerations and case studies using decortication and threaded implant fixation. *Int J Spine Surg*. 2017;11(1):8. doi:10.14444/4008
 27. Cognetti DJ, Jorgensen AY. Minimally invasive sacroiliac fusion revision: a technique guide. *Int J Spine Surg*. 2021;15(2):274–279. doi:10.14444/8037
 28. Ostelo RW, Deyo RA, Stratford P, et al. Interpreting change scores for pain and functional status in low back pain: towards international consensus regarding minimal important change. *Spine (Phila Pa 1976)*. 2008;33(1):90–94. doi:10.1097/BRS.0b013e31815e3a10
 29. Cross WW, Delbridge A, Hales D, Fielding LC. Minimally invasive sacroiliac joint fusion: 2-year radiographic and clinical outcomes with a principles-based SIJ fusion system. *Open Orthop J*. 2018;12:7–16. doi:10.2174/1874325001812010007
 30. Buchanan P, Vodapally S, Lee DW, et al. Successful diagnosis of sacroiliac joint dysfunction. *J Pain Res*. 2021;14:3135–3143. doi:10.2147/JPR.S327351
 31. Fogel GR, Toohey JS, Neidre A, Brantigan JW. Fusion assessment of posterior lumbar interbody fusion using radiolucent cages: X-ray films and helical computed tomography scans compared with surgical exploration of fusion. *Spine J*. 2008;8(4):570–577. doi:10.1016/j.spinee.2007.03.013
 32. Kaiser SP, Gardner MJ, Liu J, Routt MLC, Morshed S. Anatomic determinants of sacral dysmorphism and implications for safe iliosacral screw placement. *J Bone Joint Surg Am*. 2014;96(14):14. doi:10.2106/JBJS.M.00895
 33. Lehman RA, Kuklo TR, Belmont PJ, Andersen RC, Polly DW. Advantage of pedicle screw fixation directed into the apex of the sacral promontory over bicortical fixation: a biomechanical analysis. *Spine (Phila Pa 1976)*. 2002;27(8):806–811. doi:10.1097/00007632-200204150-00006
 34. Miller AN, RouttMLC. Variations in sacral morphology and implications for iliosacral screw fixation. *J Am Acad Orthop Surg*. 2012;20(1):8–16. doi:10.5435/JAAOS-20-01-008
 35. Sayed D, Khatri N, Rupp A, et al. Salvage of failed lateral sacroiliac joint fusion with a novel posterior sacroiliac fusion device: diagnostic approach, surgical technique, and multicenter case series. *J Pain Res*. 2022;15:1411–1420. doi:10.2147/JPR.S357076
 36. Mitchell SCW. Sacroiliac implant length and loosening: CT analysis of radiographically loose components compared to controls. In: *Orthopedic Trauma Association Annual Meeting*. Kissimmee, FL: Orthopaedic Trauma Association; 2018.
 37. Claus CF, Lytle E, Kaufmann A, et al. Minimally invasive sacroiliac joint fusion using triangular titanium versus cylindrical

threaded implants: a comparison of patient-reported outcomes. *World Neurosurg.* 2020;133:e745–e750. doi:10.1016/j.wneu.2019.09.150

38. Chang E, Rains C, Ali R, Wines RC, Kahwati LC. Minimally invasive sacroiliac joint fusion for chronic sacroiliac joint pain: a systematic review. *Spine J.* 2022;22(8):1240–1253. doi:10.1016/j.spinee.2022.01.005

39. Kaye AD, Edinoff AN, Scoon L, et al. Novel interventional techniques for chronic pain with minimally invasive arthrodesis of the sacroiliac joint: (insite, ifuse, tricor, rialto, and others). *Rheumatol Ther.* 2021;8(3):1061–1072. doi:10.1007/s40744-021-00350-8

40. Charnley J. Compression arthrodesis of the ankle and shoulder. *J Bone Joint Surg Br.* 1951;33B(2):180–191.

41. Charnley JC. Positive pressure in arthrodesis of the knee joint. *J Bone Joint Surg Br.* 1948;30B(3):478–486. doi:10.1302/0301-620X.30B3.478

42. Cunningham JL, Richardson JB, Soriano RMG, Kenwright J. A mechanical assessment of applied compression and healing in knee arthrodesis. *Clinical Orthopaedics and Related Research.* 1989;242:256. doi:10.1097/00003086-198905000-00026

43. Lauge-Pedersen H. Percutaneous arthrodesis. *Acta Orthopaedica Scandinavica.* 2003;74(307):1–33. doi:10.1080/03008820310014109

44. Slappay G, Toribatake Y, Ganey TM, Ogden JA, Hutton WC. Guidelines to decortication in posterolateral spine fusion. *J Spinal Disord.* 1998;11(2):102–109. doi:10.1097/00002517-199804000-00002

45. Dengler J, Kools D, Pflugmacher R, et al. Randomized trial of sacroiliac joint arthrodesis compared with conservative management for chronic low back pain attributed to the sacroiliac joint. *J Bone Joint Surg Am.* 2019;101(5):400–411. doi:10.2106/JBJS.18.00022

46. Duhon BS, Bitan F, Lockstadt H, et al. Triangular titanium implants for minimally invasive sacroiliac joint fusion: 2-year follow-up from a prospective multicenter trial. *Int J Spine Surg.* 2016;10:13:13. doi:10.14444/3013

47. Abbasi H, Hipp JA. The assessment of fusion following sacroiliac joint fusion surgery. *Cureus.* 2017;9(10):e1787. doi:10.7759/cureus.1787

48. Kube RA, Muir JM. Sacroiliac joint fusion: one year clinical and radiographic results following minimally invasive sacroiliac joint fusion surgery. *Open Orthop J.* 2016;10:679–689. doi:10.2174/1874325001610010679

49. Kucharzyk D, Colle K, Boone C, Araghi A. Clinical outcomes following minimally invasive sacroiliac joint fusion with decortication: the evolution clinical study. *Int J Spine Surg.* 2022;16(1):168–175. doi:10.14444/8185

Funding: The authors received no financial support for the research, authorship, and/or publication of this article.

Disclosures: William W. Cross III is a paid consultant and receives royalties from Osteocentric outside the submitted work. The remaining authors have no disclosures.

Corresponding Author: Jeremy C. Thompson, Department of Orthopedic Surgery, Mayo Clinic, 200 First St SW, Rochester, MN 55905, thompson.jeremyc@gmail.com; thompson.jeremyc@gmail.com

Published 08 February 2023

This manuscript is generously published free of charge by ISASS, the International Society for the Advancement of Spine Surgery. Copyright © 2023 ISASS. To see more or order reprints or permissions, see <http://ijssurgery.com>.